

## REVIEW ARTICLE

## MEDICAL PROGRESS

## Cancer of the Ovary

Stephen A. Cannistra, M.D.

**E**PITHELIAL CANCER OF THE OVARY IS A RELATIVELY UNCOMMON GYNECOLOGIC cancer in the United States, with approximately 25,580 new cases and 16,090 deaths anticipated in 2004.<sup>1</sup> Most patients present with advanced disease, which is managed with surgical resection followed by platinum-based chemotherapy. During the past decade, advances in chemotherapy have resulted in improved survival and in more effective treatment of relapsed disease. In addition, a better understanding of genetic risk factors has permitted a tailored approach to preventive strategies, such as bilateral salpingo-oophorectomy in selected women. This review describes the clinical features of epithelial ovarian cancer, with an emphasis on recent advances in postoperative management.

From the Program of Gynecologic Medical Oncology, Beth Israel Deaconess Medical Center, Boston. Address reprint requests to Dr. Cannistra at the Program of Gynecologic Medical Oncology, Beth Israel Deaconess Medical Center, 330 Brookline Ave., Boston, MA 02215, or at scannist@bidmc.harvard.edu.

N Engl J Med 2004;351:2519-29.

Copyright © 2004 Massachusetts Medical Society.

## EPIDEMIOLOGY AND RISK FACTORS

Epithelial cancer of the ovary derives from malignant transformation of the epithelium of the ovarian surface, which is contiguous with the peritoneal mesothelium. The median age of patients with ovarian cancer is 60 years, and the average lifetime risk for women is about 1 in 70. A strong family history of ovarian or breast cancer is the most important risk factor, although an identifiable genetic predisposition is present in only approximately 5 percent of affected women. Nulliparity is associated with an increased risk of ovarian cancer, whereas oral contraceptive use, pregnancy, and lactation are associated with a reduced risk.<sup>1,2</sup> Taken together, these observations suggest that repeated stimulation of the epithelium of the ovarian surface, which occurs in the nulliparous state as a result of uninterrupted ovulation, may predispose the epithelium to malignant transformation. Although early reports suggested that fertility drugs might increase the risk of ovarian cancer, subsequent studies that adjusted for parity and the duration of infertility have not confirmed these results.<sup>3-5</sup> Women who have undergone tubal ligation appear to be at lower risk than those who have not, although the mechanism is unclear.<sup>6</sup>

## FAMILIAL SYNDROMES

A strong family history of breast cancer, ovarian cancer, or both — sometimes occurring at an early age and in the same woman — may be related to the presence of an inherited mutation in one of two genes, known as *BRCA1* and *BRCA2*. The *BRCA1* and *BRCA2* genes are located on chromosomes 17q and 13q, respectively, and their gene products are involved in DNA repair.<sup>7,8</sup> Because a mutated allele for the *BRCA1* or *BRCA2* gene may be inherited from either parent, it is important to obtain a complete family history during risk assessment.

Certain ethnic groups, such as Ashkenazi Jews, have an increased probability of harboring germ-line *BRCA1* or *BRCA2* mutations. The three most common mutations that occur in healthy Ashkenazi Jewish women are the 185delAG mutation in *BRCA1*,

the 5382insC mutation in *BRCA1*, and the 6174delT mutation in *BRCA2*, with a collective prevalence of approximately 2.5 percent.<sup>9,10</sup> Among Ashkenazi Jewish women with a known diagnosis of ovarian cancer, however, the frequency of such mutations has been reported to be as high as 26 to 41 percent.<sup>9-12</sup> Women with a germ-line mutation in *BRCA1* are reported to have a lifetime risk of ovarian cancer that ranges from 16 to 44 percent, and a lifetime risk of breast cancer that ranges from 56 to 87 percent.<sup>12,13</sup> Ovarian cancer may develop at an earlier age in women with germ-line *BRCA1* mutations than in those with the sporadic form of the disease, although it is important to recognize that ovarian cancer may occur at any age in mutation carriers.

Like *BRCA1*, the *BRCA2* protein is localized in the nucleus and is involved in DNA repair through its association with the protein RAD51.<sup>14</sup> Women with germ-line mutations in *BRCA2* have a lifetime risk of breast cancer that is similar to that for carriers of the *BRCA1* mutation, and their lifetime risk of ovarian cancer is approximately 10 percent.<sup>12,15</sup> Men with *BRCA1* or *BRCA2* mutations are at risk for male breast cancer and may also have an increased risk for developing pancreatic cancer, as compared with men who do not have the mutation.<sup>15,16</sup> The natural history of ovarian cancer that develops in the setting of *BRCA1* or *BRCA2* germ-line mutations appears to be characterized by a more indolent course than that of sporadic disease.<sup>9,17</sup>

A second familial disorder that carries with it an increased risk of ovarian cancer is referred to as the Lynch syndrome II; it is caused by inherited germ-line mutations in DNA mismatch repair genes, such as *MSH2* (mutS homologue 2) or *MLH1* (mutL homologue 1).<sup>18</sup> Affected families have a predominance of hereditary nonpolyposis colon cancer, often on the right side of the colon and sometimes in association with other cancers, such as those of the endometrium, ovaries, or genitourinary tract.

---

#### PROPHYLACTIC TREATMENT FOR WOMEN WITH GERM-LINE MUTATIONS IN *BRCA1* OR *BRCA2*

---

Women with a known germ-line mutation in *BRCA1* or *BRCA2* who have completed childbearing may reduce their risk of ovarian cancer by undergoing bilateral salpingo-oophorectomy, which is the preventive measure of choice in this setting.<sup>19,20</sup> Since

mutation carriers are at increased risk for cancer of the fallopian tube, removal of the fallopian tubes as part of prophylactic surgery is advisable, and some investigators have also considered hysterectomy to ensure removal of the stump of the fallopian tubes.<sup>21</sup> Although prophylactic bilateral salpingo-oophorectomy can reduce the risk of ovarian cancer, patients with *BRCA1* or *BRCA2* germ-line mutations appear to be at persistent risk for primary peritoneal serous carcinoma, which can develop after the prophylactic surgery.<sup>22,23</sup> For instance, in a retrospective study, Piver et al. reported that over a period of 1 to 27 years, primary peritoneal serous carcinoma developed in 6 of 324 women who had previously undergone prophylactic oophorectomy.<sup>24</sup> This disease entity, which resembles epithelial ovarian cancer clinically and histologically, is thought to represent malignant transformation of the peritoneal mesothelial surface. Prophylactic bilateral salpingo-oophorectomy in women with *BRCA1* or *BRCA2* germ-line mutations has also been reported to reduce the risk of breast cancer, presumably by decreasing levels of circulating estrogen, progesterone, or both.<sup>19,20</sup> Accordingly, the use of estrogen-replacement therapy in women who undergo this procedure is currently a matter of controversy.<sup>25</sup> It is beyond the scope of this review to discuss other risk-reduction strategies for breast cancer, such as screening, prophylactic mastectomy, or chemoprevention in the high-risk setting.<sup>26</sup>

For patients at high risk for ovarian cancer who decide not to undergo prophylactic bilateral salpingo-oophorectomy, screening that includes frequent pelvic examinations, measurement of serum CA-125 levels, and the performance of transvaginal pelvic ultrasonography is often considered. However, it is important to stress that early ovarian cancer often evades such screening strategies, and the effectiveness of screening for ovarian cancer in the high-risk setting has not yet been demonstrated.<sup>27</sup> Similarly, for women at average risk for ovarian cancer (i.e., those with no known genetic predisposition), there is no conclusive evidence of a benefit of routine screening that consists of measurement of serum CA-125 levels, pelvic ultrasonography, or both.<sup>28</sup> At least two randomized trials are currently in progress to evaluate the role of screening in this disease.<sup>29</sup> Finally, the benefit of using oral contraceptives to reduce the risk of ovarian cancer in mutation carriers is uncertain.<sup>30,31</sup> Modan et al.<sup>30</sup> reported no benefit of oral-contraceptive prophylaxis

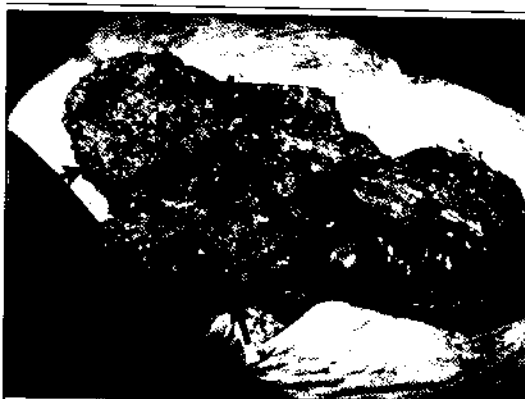in women with *BRCA1* or *BRCA2* germ-line mutations, whereas an earlier study by Narod et al.<sup>31</sup> had suggested there was possible benefit.

### CLINICAL PRESENTATION

The symptoms of ovarian cancer are nonspecific and often suggest the presence of upper abdominal disease (Fig. 1). Patients may report abdominal fullness, dyspepsia, early satiety, or bloating as the result of increased abdominal pressure from ascites or involvement of the omentum. Occasionally, patients with early-stage disease present with pelvic pain due to ovarian torsion, although most patients with early-stage disease are asymptomatic. Physical findings are diverse and typically include a palpable ovarian mass. In this regard, ovarian cancer should be considered in any premenopausal woman with an unexplained enlargement of the ovary or any postmenopausal woman with a palpable ovary.

Other findings on physical examination may include ascites, pleural effusions, and an umbilical mass referred to as a Sister Mary Joseph's nodule. Such umbilical masses are rare and nonspecific; they can be associated with gastric, pancreatic, gallbladder, colon, and appendiceal cancers. The most common extraabdominal site of disease is the pleural space, although lung parenchymal involvement may be observed on occasion. Paraneoplastic phenomena include humorally mediated hypercalcemia with clear-cell histologic findings,<sup>32</sup> as well as subacute cerebellar degeneration associated with anti-Purkinje-cell antibodies.<sup>33</sup> The Leser-Trélat sign is characterized by the sudden appearance of seborrheic keratoses and, on rare occasions, has been reported to herald the development of ovarian cancer.<sup>34</sup> Trousseau's syndrome (migratory superficial thrombophlebitis), palmar fasciitis, dermatomyositis, and polyarthritides have also been observed.<sup>35-37</sup>

If ovarian cancer is suspected on the basis of symptoms and physical examination, transvaginal ultrasonography is often performed for further evaluation of the pelvis. Transvaginal ultrasonography appears to be more sensitive than computed tomographic (CT) scanning for the detection of pelvic masses, and it provides qualitative information about the mass that is useful for further management decisions.<sup>38,39</sup> Specifically, the finding of a complex ovarian cyst, defined by the presence of both solid and cystic components, sometimes with

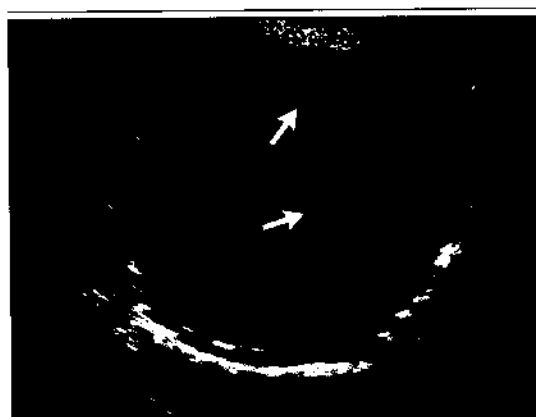

**Figure 1. Typical Intraoperative Appearance of Stage III Epithelial Ovarian Cancer.**

The entire omentum (arrows) has been replaced by multiple tumor implants. (Photograph courtesy of Dr. Young B. Kim, Beth Israel Deaconess Medical Center, Boston.)

septations and internal echoes, is highly suggestive of cancer (Fig. 2). Such cysts typically require surgery for definitive diagnosis. Percutaneous biopsy of complex cysts is to be avoided, given the risk of tumor spillage into the pelvic cavity. In contrast, simple ovarian cysts have smooth walls, are filled with fluid, and do not contain a solid component. These cysts are often benign and generally do not require immediate surgical intervention, although careful follow-up is recommended.<sup>39</sup>

Although the serum CA-125 level is elevated in more than 80 percent of patients with advanced epithelial ovarian cancer, this measurement alone is neither sufficiently sensitive nor specific enough to be diagnostic.<sup>40-42</sup> Elevated serum CA-125 levels may be associated with various conditions, such as pregnancy, endometriosis, adenomyosis, uterine fibroids, pelvic inflammatory disease, menstruation, and benign cysts. The serum CA-125 level may also be elevated in other malignant conditions, such as pancreatic, breast, lung, gastric, and colon cancers. Thus, measurement of the CA-125 level is not usually helpful in the preoperative evaluation of a complex ovarian cyst, and surgery is generally necessary for definitive diagnosis. However, a serum CA-125 level of more than 65 U per milliliter in a postmenopausal woman with an abdominal or pelvic mass should raise the possibility of ovarian cancer, prompting consultation with a gynecologic oncologist before surgery.<sup>43</sup> Finally, the CA-125 level is useful in assessing the patient's response to



**Figure 2. Typical Appearance of a Complex Cyst on a Transvaginal Ultrasonogram.**

Arrows indicate solid components within the fluid-filled cyst. (Ultrasonogram courtesy of Dr. Ann McNamara, Beth Israel Deaconess Medical Center, Boston.)

postoperative chemotherapy and in detecting early relapse in patients who have already received a diagnosis of ovarian cancer.<sup>44</sup>

#### SURGERY

If ovarian cancer is suspected on the basis of the physical examination and the results of transvaginal ultrasonography, an exploratory laparotomy is usually performed for histologic confirmation, staging, and tumor debulking. Histologic confirmation is necessary to rule out other causes of a complex ovarian cyst, including nonepithelial ovarian cancers (e.g., stromal or germ-cell tumors), metastatic disease to the ovary from another primary site (e.g., Krukenberg's tumors), or benign conditions, such as an endometriotic cyst.<sup>45-47</sup> Krukenberg's tumors are typically signet-ring-cell neoplasms that represent metastatic disease to the ovary from a primary gastric adenocarcinoma.<sup>48</sup> However, the ovary may be the site of metastases from other primary sites such as the colon, appendix, gallbladder, and breast (especially infiltrating lobular carcinoma).<sup>46</sup> Surgical staging, performed during exploratory laparotomy, provides important information that can guide postoperative decision making, especially for early-stage disease (as discussed below). Finally, tumor debulking (primary cytoreduction) is a valuable component of initial surgery, since patients with residual tumor 1 cm or less in diameter have higher survival rates than those with more extensive residual disease.<sup>49</sup>

The standard surgical approach involves a vertical midline incision to permit adequate exposure of the upper abdomen and pelvis. A total abdominal hysterectomy and bilateral salpingo-oophorectomy are typically performed, along with careful examination of all peritoneal surfaces, omentectomy, biopsy of para-aortic lymph nodes when appropriate, random biopsies of clinically uninvolved areas, and peritoneal washings. Biopsy of the para-aortic nodes is especially important in patients with disease that otherwise appears to be limited to the ovary, since such patients may have more advanced disease.<sup>50</sup> The staging system for ovarian cancer, established by the International Federation of Gynecology and Obstetrics, is shown in Table 1.<sup>45</sup> Rates of long-term survival among patients with early-stage disease (stage I or II) can be as high as 80 to 95 percent, whereas patients with advanced disease (stage III or IV) have lower survival rates (10 to 30 percent).<sup>51,52</sup> The most common histologic type of epithelial ovarian cancer is the papillary serous variant, which is often associated with concentric rings of calcification known as psammoma bodies (Fig. 3). Other histologic types and associated clinical features are listed in Table 2.<sup>53-55</sup>

Although initial surgery is almost always necessary in the management of suspected ovarian cancer, it is important to recognize at least two groups of patients for whom alternative approaches might be considered. The first group includes patients with a complex ovarian cyst and iron-deficiency anemia due to occult gastrointestinal bleeding. Clinical suspicion of a Krukenberg's metastasis from a gastric or other gastrointestinal primary site should prompt an initial endoscopic evaluation (e.g., upper endoscopy, colonoscopy, or both as clinically indicated) before it is determined whether a surgical procedure might be necessary (Fig. 4).

The second group includes patients with suspected ovarian cancer who are poor candidates for surgery because of a coexisting disease that precludes the performance of a safe cytoreductive procedure. In this situation, it is reasonable to establish the diagnosis of presumed ovarian cancer by obtaining a confirmatory biopsy specimen or a specimen for cytology (e.g., from a peritoneal implant or from ascitic fluid), followed by the administration of platinum-based chemotherapy, as described below. If the patient has a response to treatment and becomes a more appropriate surgical candidate, it is reasonable to attempt tumor debulking after three cycles of chemotherapy have

been administered<sup>56</sup> (Fig. 4). However, this procedure, known as interval cytoreduction, does not appear to benefit patients in whom optimal debulking could not be achieved by an experienced gynecologic oncologist at the time of initial surgery.<sup>57</sup>

#### POSTOPERATIVE CHEMOTHERAPY

##### EARLY-STAGE DISEASE

The majority of patients with epithelial ovarian cancer will require postoperative adjuvant chemotherapy in an attempt to eradicate residual disease. Nonetheless, it is possible to identify a subgroup of patients with early-stage disease who have a five-year survival rate of 90 to 95 percent after surgery alone, for whom the rate of survival is not improved by the use of postoperative adjuvant chemotherapy.<sup>51</sup> This low-risk subgroup includes patients with stage IA, grade 1 disease; many investigators also include in this group patients with stage IA, grade 2 disease, or stage IB, grade 1 or 2 disease (Table 1).<sup>51,58</sup> For carefully selected patients, such as those with stage IA, grade 1 disease who wish to preserve fertility, a unilateral salpingo-oophorectomy might be considered, assuming that adequate staging has been performed.<sup>59</sup> In this situation, if the ovarian histologic type is categorized as endometrioid (Table 2), it is reasonable to perform an endometrial biopsy in order to rule out a synchronous uterine cancer.<sup>53</sup>

Patients with early-stage ovarian cancer who are at high risk for relapse include those with stage IC disease; those with stage I, grade 3 disease; and those with stage II disease (Table 1). Platinum-based adjuvant treatment can reduce the risk of relapse in this group, resulting in disease-free survival of approximately 80 percent.<sup>58,60</sup> In addition, findings in two randomized trials from Europe suggest that platinum-based chemotherapy is associated with an overall survival advantage in high-risk patients with early-stage disease, although the benefit appears to be restricted to those patients in whom staging was incomplete.<sup>58,61</sup>

For the reasons outlined below, postoperative chemotherapy with paclitaxel and carboplatin is commonly considered for high-risk patients with early-stage ovarian cancer, although there is controversy regarding the number of cycles necessary to achieve the optimal benefit. A randomized trial conducted by the Gynecologic Oncology Group that compares three cycles with six cycles of paclitaxel and carboplatin chemotherapy in early-stage

Table 1. Staging System for Epithelial Ovarian Cancer.\*

Stage	Characteristics
I	Tumor limited to ovary or ovaries†
A	One ovary involved, without ascites, positive peritoneal washings, surface involvement, or rupture
B	Both ovaries involved, without ascites, positive peritoneal washings, surface involvement, or rupture
C	Ascites, positive peritoneal washings, surface involvement, or rupture present
II	Ovarian tumor with pelvic extension†
A	Involvement of the uterus or fallopian tubes
B	Involvement of other pelvic organs (e.g., bladder, rectum, or pelvic sidewall)
C	Pelvic extension, plus findings indicated for stage IC
III	Tumor involving the upper abdomen or lymph nodes
A	Microscopical disease outside the pelvis, typically involving the omentum
B	Gross deposits ≤2 cm in diameter‡
C	Gross deposits >2 cm in diameter or nodal involvement‡
IV	Distant organ involvement, including pleural space or hepatic or splenic parenchyma§

\* Guidelines are from the International Federation of Gynecology and Obstetrics.

† Patients with disease that appears to be confined to the ovaries or pelvis require nodal biopsy for complete staging in order to rule out the possibility of occult stage IIIC disease.

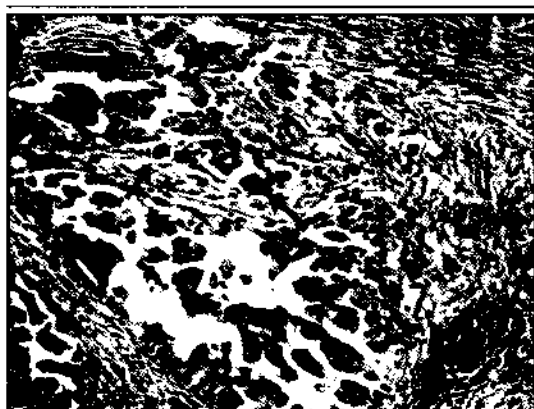
‡ Disease measurements for staging purposes are made before debulking has been attempted.

§ Pleural effusion must be cytologically proven to be malignant if used to define stage IV disease.

disease has thus far shown no significant difference in overall survival, but a higher relapse rate has been reported in patients receiving the three-cycle regimen.<sup>62,63</sup> Although adjuvant radiotherapy of the whole abdomen is sometimes considered in selected high-risk patients with early-stage disease, platinum-based chemotherapy has been more extensively studied and is more widely used.

##### ADVANCED DISEASE

Intravenous administration of taxane- and platinum-based chemotherapy is the current standard of postoperative care for patients with advanced ovarian cancer. Platinum analogues, such as carboplatin and cisplatin, are the most active agents in this disease, mediating their effects through the formation of intrastrand cross-links with DNA. In contrast, taxanes such as paclitaxel and docetaxel exert their cytotoxic effects through a unique mech-



**Figure 3. Papillary Serous Ovarian Cancer (Hematoxylin and Eosin).**

Arrows show areas of psammoma-body formation. (Photomicrograph courtesy of Dr. Jonathan Hecht, Beth Israel Deaconess Medical Center, Boston.)

**Table 2. Common Histologic Types of Epithelial Ovarian Cancer.**

Histologic Type	Features
Papillary serous	The most common type of epithelial ovarian cancer; may contain psammoma bodies and often associated with elevated CA-125 levels; histologic features identical to those of primary peritoneal serous cancer
Endometrioid	Sometimes associated with endometriosis, a separate primary uterine cancer with similar histologic features, or both; may occur with early-stage disease in younger patients, although advanced disease is also possible
Mucinous	May be associated with pseudomyxoma peritonei (rarely); CA-125 levels may not be markedly elevated; like clear-cell ovarian cancer, relatively resistant to chemotherapy; not typically associated with <i>BRCA1</i> or <i>BRCA2</i> germ-line mutations; differential diagnosis includes metastatic disease from primary cancer of the appendix, especially if ovarian involvement is bilateral
Clear-cell	The most chemoresistant type of ovarian cancer; characterized by hobnail-shaped tumor cells with cleared-out cytoplasm; sometimes associated with endometriosis, humorally mediated hypercalcemia, or both

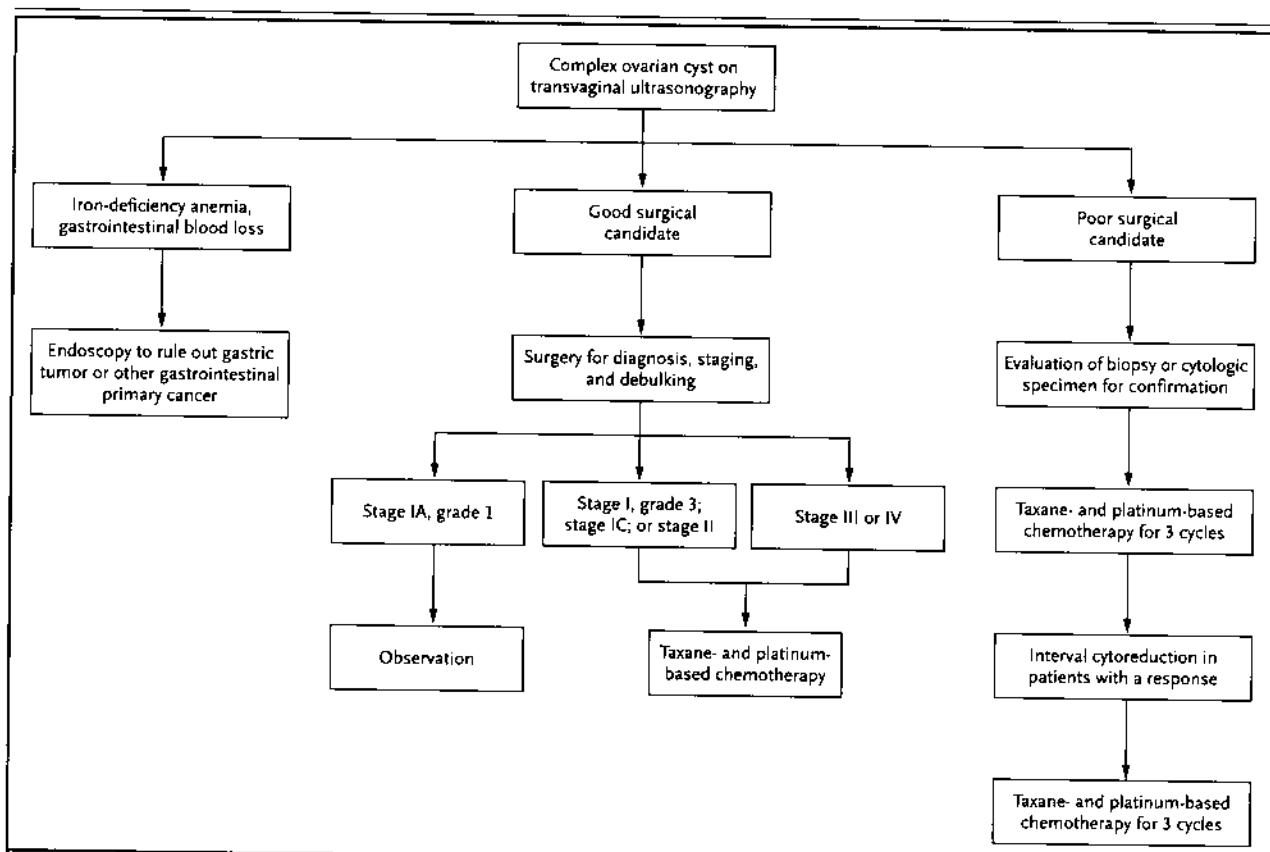
anism of action involving binding to and stabilization of the tubulin polymer.<sup>64</sup> The results of two randomized trials show that combination chemotherapy with paclitaxel and cisplatin prolongs both progression-free and overall survival in patients with advanced disease as compared with older regimens that do not contain taxanes.<sup>52,65</sup> The median overall survival for patients whose tumor burden could not be optimally debulked (those with residual tu-

mor greater than 1 cm in diameter) was 37 months among those treated with paclitaxel and cisplatin as compared with 25 months for those receiving cyclophosphamide and cisplatin.<sup>52</sup>

Overall, the inclusion of paclitaxel in first-line therapy appears to result in a 30 percent reduction in the risk of death.<sup>52,65</sup> A third randomized trial that included paclitaxel as part of first-line chemotherapy showed no improvement in survival, for reasons that are still poorly understood.<sup>66,67</sup> More recently, the combination of paclitaxel and carboplatin was reported to be as effective as paclitaxel and cisplatin as first-line therapy, but with less emesis, leukopenia, and nephropathy.<sup>68,69</sup> Remarkably, for patients with advanced-stage disease who had undergone optimal debulking, the paclitaxel-and-carboplatin regimen resulted in a median overall survival of almost five years.<sup>68</sup> Although most patients can undergo this regimen without difficulty, the development of peripheral neuropathy may impair the quality of life for some patients.<sup>68</sup> In this regard, the use of docetaxel in combination with carboplatin may result in less neuropathy and equivalent efficacy but greater myelosuppression than the combination of paclitaxel and carboplatin.<sup>70</sup>

Despite the improved median overall survival in patients with regimens such as paclitaxel and carboplatin, relapse still occurs in the majority of those with advanced disease, and only 10 to 30 percent of such patients have long-term survival. The increasing availability of options for second-line chemotherapy that are sometimes capable of controlling recurrent disease for prolonged periods of time will probably lead to further improvements in survival.

More than 50 percent of patients with advanced disease who receive chemotherapy with paclitaxel and carboplatin have a complete clinical remission as defined by normal findings on physical examination, CA-125 testing, and CT scanning.<sup>52,68</sup> Patients who have a complete clinical remission are typically monitored with serial physical examinations and CA-125 measurements, with radiographic studies such as CT scanning performed as clinically indicated for suspicious symptoms, abnormalities on physical examination, or elevated CA-125 levels. Although a "second-look" laparotomy appears to be capable of detecting subclinical disease in up to 75 percent of such patients, the therapeutic value of this procedure is dubious in the absence of potentially curative salvage therapy.<sup>68</sup>



**Figure 4. Approach to the Patient with a Complex Ovarian Cyst.**

In addition to patients with stage IA, grade 1 disease, those with stage IA, grade 2 disease or stage IB, grade 2 or 3 disease are often included in the low-risk category. Clear-cell histologic findings represent grade 3 disease. Poor surgical candidates include patients whose health has been impaired by coexisting disease or by widespread tumor that compromises the performance of a safe cytoreductive procedure. Interval cytoreduction is considered for patients who did not undergo technically adequate surgical cytoreduction at the time of diagnosis. However, for patients who have undergone a technically adequate procedure, and in whom cytoreduction was suboptimal (those with residual tumor exceeding 1 cm in diameter), interval cytoreduction does not appear to confer an added benefit. Six cycles of paclitaxel and carboplatin are typically administered in patients with advanced disease, although the optimal duration of treatment for patients with early-stage disease who are at high risk has not been well defined.

Thus, second-look laparotomy is generally not performed outside a clinical-trial setting.

Despite receiving highly active first-line chemotherapy, approximately 20 to 30 percent of patients never have a clinical remission and continue to have evidence of residual or progressive disease during treatment. Features that are predictive of inferior survival include an advanced tumor stage, an age of more than 65 years, suboptimal debulking, high-grade or clear-cell histologic findings, preoperative ascites, a CA-125 level that has not reached the normal range within three cycles of therapy, and a CA-125 nadir of more than 20 U per milliliter at the completion of first-line therapy.<sup>49,54,71-73</sup>

#### MANAGEMENT OF RECURRENT DISEASE

Disease recurrence continues to be a major problem for patients with advanced ovarian cancer. Since recurrent disease is generally not curable, palliation of symptoms and prevention of complications, such as bowel obstruction, are the goals of management. A common sign of relapse is a rise in the serum CA-125 level in the absence of symptoms and abnormalities on physical examination or CT scanning.<sup>74</sup> Referred to as marker-only relapse, it usually antedates the development of clinically obvious tumor, with a median duration of at least three

months.<sup>75</sup> Because the primary goal of the management of recurrent disease is palliation, and because there is no compelling evidence that early institution of cytotoxic chemotherapy is beneficial in a typical patient with marker-only relapse, hormonal therapy, such as tamoxifen or an aromatase inhibitor, is often considered in this situation.<sup>76,77</sup> Less than 20 percent of patients have a response to hormonal therapy, although an occasional patient has a dramatic reduction in the CA-125 level, and some patients may have a prolonged period of stable disease, thus avoiding the side effects of cytotoxic treatment.

Eventually, patients with marker-only relapse have disease progression that warrants the institution of second-line chemotherapy. The choice of cytotoxic agents generally depends on the duration of the prior remission. Patients who have a relapse more than six months after the completion of first-line therapy may have platinum-sensitive disease, with response rates of 30 percent or greater.<sup>78,79</sup> For patients who have platinum-sensitive disease, minimal symptoms, and a small tumor burden, single-agent chemotherapy with carboplatin is a reasonable option that is often well tolerated, without appreciable alopecia. Combination platinum-based chemotherapy may be a reasonable consideration for selected patients, especially those who have more severe symptoms and rapidly progressive disease.<sup>80,81</sup> For patients who have a relapse after a relatively long first remission (more than 6 to 12 months), tumor debulking (secondary cytoreduction) is sometimes considered before chemotherapy if the tumor is technically resectable. However, this approach has never been tested in a randomized trial.<sup>82</sup>

Patients with a short remission, lasting less than six months after first-line chemotherapy, usually (but not always) have platinum-resistant disease<sup>83</sup> and are often treated with a regimen that does not contain platinum. Furthermore, occasional patients who receive platinum-based regimens for relapsed disease have progressive neuropathy, cumulative thrombocytopenia, or a platinum allergy<sup>84</sup> that necessitates a switch to an alternative agent. Agents that can be considered include liposomal doxorubicin, topotecan, gemcitabine, paclitaxel, oral etoposide, and vinorelbine.<sup>78,85-89</sup> Since the reported response rate for each of these drugs is in the 10 to 20 percent range in patients with platinum-resistant disease, the choice is often driven by the side-effect profile and the convenience of administration. For

instance, liposomal doxorubicin is administered once per month, with minimal alopecia, nausea, or myelosuppression, making it a reasonable option when palliation is the major goal.<sup>90</sup> Approximately 20 to 30 percent of patients who receive treatment with liposomal doxorubicin will have the hand-foot syndrome (palmar-plantar erythrodysesthesia), which is characterized by erythema, tenderness, and blister formation on the palms, soles, and other cutaneous pressure points and which is sometimes associated with mucositis. Responses to liposomal doxorubicin (as well as to other agents used in patients with relapse) may be delayed, requiring three or four cycles before a benefit becomes evident. Topotecan is another valid choice for the treatment of relapse; the use of a weekly dosing schedule has been shown to improve tolerance.<sup>87</sup> Although liposomal doxorubicin and topotecan have been studied most extensively as single agents for the treatment of platinum-resistant disease, the other agents mentioned may be useful as well. Additional clinical trials are required to identify more effective options for patients with relapsed disease.

---

#### PROSPECTS FOR A BRIGHTER FUTURE

---

The outlook for patients with epithelial ovarian cancer has clearly improved over the past decade, largely as a result of taxane- and platinum-based first-line chemotherapy, as well as an increase in options for the management of recurrent disease. In addition, it is now commonplace for the internist, oncologist, and genetics counselor to work together in recognizing familial syndromes and implementing risk-reduction strategies, such as prophylactic bilateral salpingo-oophorectomy in selected women. Although there is currently no screening strategy for ovarian cancer with proven effectiveness, approaches such as proteomics and assessment of CA-125 kinetics hold promise for the future.<sup>91,92</sup> From a treatment perspective, the inclusion of drugs such as gemcitabine, liposomal doxorubicin, and topotecan in the first-line setting is under investigation.<sup>93,94</sup> Intraperitoneal administration of first-line chemotherapy is also being evaluated, and strategies to maintain remission with the use of drugs such as paclitaxel are also of interest.<sup>95-101</sup> Several molecular targets for drug development have been identified, including pathways mediated by p53, lysophosphatidic acid, the BCL-2 family, the epidermal growth factor receptor (EGFR), and



the vascular endothelial growth factor receptor (VEGFR).<sup>102-109</sup> Clinical trials are already being designed to evaluate agents that inhibit the VEGFR or EGFR pathway in patients with newly diagnosed disease and in those with marker-only relapse. Finally, the use of microarray gene-expression profiling holds promise as a prognostic tool and may

provide insight into the mechanisms of drug resistance, which frequently develops in this tumor.<sup>110</sup> There is hope that a combination of these approaches will further improve the survival of patients with this often lethal disease.

Dr. Cannistra reports having received lecture fees from Ortho and GlaxoSmithKline and grant support from GlaxoSmithKline, Pfizer, and Aventis.

## REFERENCES

- Schildkraut JM, Thompson WD. Familial ovarian cancer: a population-based case-control study. *Am J Epidemiol* 1988;128:456-66.
- Whittemore AS. Characteristics relating to ovarian cancer risk: implications for prevention and detection. *Gynecol Oncol* 1994;55:S15-S19.
- Rosling MA, Daling JR, Weiss NS, Moore DE, Self SG. Ovarian tumors in a cohort of infertile women. *N Engl J Med* 1994;331:771-6.
- Venn A, Watson L, Lumley J, Giles G, King C, Healy D. Breast and ovarian cancer incidence after infertility and in vitro fertilisation. *Lancet* 1995;346:995-1000.
- Ness RB, Cramer DW, Goodman MT, et al. Infertility, fertility drugs, and ovarian cancer: a pooled analysis of case-control studies. *Am J Epidemiol* 2002;155:217-24.
- Hankinson SE, Hunter DJ, Colditz GA, et al. Tubal ligation, hysterectomy, and risk of ovarian cancer: a prospective study. *JAMA* 1993;270:2813-8.
- King MC, Marks JH, Mandell JB. Breast and ovarian cancer risks due to inherited mutations in BRCA1 and BRCA2. *Science* 2003;302:643-6.
- Scully R, Ganesan S, Brown M, et al. Location of BRCA1 in human breast and ovarian cancer cells. *Science* 1996;272:123-6.
- Ben David Y, Chetrit A, Hirsh-Yechezkel G, et al. Effect of BRCA mutations on the length of survival in epithelial ovarian tumors. *J Clin Oncol* 2002;20:463-6.
- Moslehi R, Chu W, Karlan B, et al. BRCA1 and BRCA2 mutation analysis of 208 Ashkenazi Jewish women with ovarian cancer. *Am J Hum Genet* 2000;66:1259-72.
- Muto MG, Cramer DW, Tangir J, Berkowitz R, Mok S. Frequency of the BRCA1 185delAG mutation among Jewish women with ovarian cancer and matched population controls. *Cancer Res* 1996;56:1250-2.
- Struwing JP, Hartge P, Wacholder S, et al. The risk of cancer associated with specific mutations of BRCA1 and BRCA2 among Ashkenazi Jews. *N Engl J Med* 1997;336:1401-8.
- Ford D, Easton DF, Bishop DT, Narod SA, Goldgar DE. Risks of cancer in BRCA1-mutation carriers. *Lancet* 1994;343:692-5.
- Tavtigian SV, Simard J, Rommens J, et al. The complete BRCA2 gene and mutations in chromosome 13q-linked kindreds. *Nat Genet* 1996;12:333-7.
- Tonin P, Weber B, Offit K, et al. Frequency of recurrent BRCA1 and BRCA2 mutations in Ashkenazi Jewish breast cancer families. *Nat Med* 1996;2:1179-83.
- Frank TS, Deffenbaugh AM, Reid JE, et al. Clinical characteristics of individuals with germline mutations in BRCA1 and BRCA2: analysis of 10,000 individuals. *J Clin Oncol* 2002;20:1480-90.
- Rubin SC, Benjamin I, Behbakht K, et al. Clinical and pathological features of ovarian cancer in women with germ-line mutations of BRCA1. *N Engl J Med* 1996;335:1413-6.
- Chung DC, Rustgi AK. The hereditary nonpolyposis colorectal cancer syndrome: genetics and clinical implications. *Ann Intern Med* 2003;138:560-70.
- Rebbeck TR, Lynch HT, Neuhausen SL, et al. Prophylactic oophorectomy in carriers of BRCA1 or BRCA2 mutations. *N Engl J Med* 2002;346:1616-22.
- Kauff ND, Satagopan JM, Robson ME, et al. Risk-reducing salpingo-oophorectomy in women with a BRCA1 or BRCA2 mutation. *N Engl J Med* 2002;346:1609-15.
- Paley PJ, Swisher EM, Garcia RL, et al. Occult cancer of the fallopian tube in BRCA-1 germline mutation carriers at prophylactic oophorectomy: a case for recommending hysterectomy at surgical prophylaxis. *Gynecol Oncol* 2001;80:176-80.
- Bandera CA, Muto MG, Schorge JO, Berkowitz RS, Rubin SC, Mok SC. BRCA1 gene mutations in women with papillary serous carcinoma of the peritoneum. *Obstet Gynecol* 1998;92:596-600.
- Levine DA, Argenta PA, Yee CJ, et al. Fallopian tube and primary peritoneal carcinomas associated with BRCA mutations. *J Clin Oncol* 2003;21:4222-7.
- Piver MS, Jishi ME, Tsukada Y, Nava G. Primary peritoneal carcinoma after prophylactic oophorectomy in women with a family history of ovarian cancer: a report of the Gilda Radner Familial Ovarian Cancer Registry. *Cancer* 1993;71:2751-5.
- Garber JE, Hartman AR. Prophylactic oophorectomy and hormone replacement therapy: protection at what price? *J Clin Oncol* 2004;22:978-80.
- Armstrong K, Eisen A, Weber B. Assessing the risk of breast cancer. *N Engl J Med* 2000;342:564-71.
- Burke W, Daly M, Garber J, et al. Recommendations for follow-up care of individuals with an inherited predisposition to cancer. II. BRCA1 and BRCA2. *JAMA* 1997;277:997-1003.
- NIH consensus conference: ovarian cancer — screening, treatment, and follow-up. *JAMA* 1995;273:491-7.
- Menon U, Jacobs IJ. Ovarian cancer screening in the general population: current status. *Int J Gynecol Cancer* 2001;Suppl 1:3-6.
- Modan B, Hartge P, Hirsh-Yechezkel G, et al. Parity, oral contraceptives, and the risk of ovarian cancer among carriers and non-carriers of a BRCA1 or BRCA2 mutation. *N Engl J Med* 2001;345:235-40.
- Narod SA, Risch H, Moslehi R, et al. Oral contraceptives and the risk of hereditary ovarian cancer. *N Engl J Med* 1998;339:424-8.
- Tsunematsu R, Saito T, Iguchi H, Fukuda T, Tsukamoto N. Hypercalcemia due to parathyroid hormone-related protein produced by primary ovarian clear cell adenocarcinoma: case report. *Gynecol Oncol* 2000;76:218-22.
- Furueux HM, Rosenblum MK, Dalmau J, et al. Selective expression of Purkinje-cell antigens in tumor tissue from patients with paraneoplastic cerebellar degeneration. *N Engl J Med* 1990;322:1844-51.
- Holguin T, Padilla RS, Ampuero E. Ovarian adenocarcinoma presenting with the sign of Leser-Trelat. *Gynecol Oncol* 1986;25:128-32.
- Raffel GD, Gravallesse EM, Schwab P, Joseph JT, Cannistra SA. Diagnostic dilemmas in oncology: case 2: dermatomyositis and ovarian cancer. *J Clin Oncol* 2001;19:4341-3.
- Evans TR, Mansi JL, Bevan DH. Trousseau's syndrome in association with ovarian carcinoma. *Cancer* 1996;77:2544-9.
- Medsker TA, Dixon JA, Garwood VE. Palmar fasciitis and polyarthritides associated with ovarian carcinoma. *Ann Intern Med* 1982;96:424-31.
- van Nagell JR Jr, Ueland FR. Ultrasound evaluation of pelvic masses: predictors of malignancy for the general gynecologist. *Curr Opin Obstet Gynecol* 1999;11:45-9.
- Granberg S, Wikland M, Jansson I. Macroscopic characterization of ovarian tumors and the relation to the histological diagno-

- sis: criteria to be used for ultrasound evaluation. *Gynecol Oncol* 1989;35:139-44.
40. Bast RC Jr, Klug TL, St John E, et al. A radioimmunoassay using a monoclonal antibody to monitor the course of epithelial ovarian cancer. *N Engl J Med* 1983;309:883-7.
41. Bast RC Jr, Siegal FP, Runowicz C, et al. Elevation of serum CA 125 prior to diagnosis of an epithelial ovarian carcinoma. *Gynecol Oncol* 1985;22:115-20.
42. Bast RC Jr, Knapp RC. Use of the CA 125 antigen in diagnosis and monitoring of ovarian carcinoma. *Eur J Obstet Gynecol Reprod Biol* 1985;19:354-6.
43. Eltabbakh GH, Belinson JL, Kennedy AW, Gupta M, Webster C, Blumenson LE. Serum CA-125 measurements > 65 U/mL: clinical value. *J Reprod Med* 1997;42:617-24.
44. Meyer T, Rustin GJ. Role of tumour markers in monitoring epithelial ovarian cancer. *Br J Cancer* 2000;82:1535-8.
45. Schumer ST, Cannistra SA. Granulosa cell tumor of the ovary. *J Clin Oncol* 2003;21:1180-9.
46. Petru E, Pickel H, Heydarfadai M, et al. Nongenital cancers metastatic to the ovary. *Gynecol Oncol* 1992;44:83-6.
47. Young RH, Gilks CB, Scully RE. Mucinous tumors of the appendix associated with mucinous tumors of the ovary and pseudomyxoma peritonei: a clinicopathological analysis of 22 cases supporting an origin in the appendix. *Am J Surg Pathol* 1991;15:415-29.
48. Holtz F, Hart WR. Krukenberg tumors of the ovary: a clinicopathologic analysis of 27 cases. *Cancer* 1982;50:2438-47.
49. Bristow RE, Tomacruz RS, Armstrong DK, Trimble EL, Montz FJ. Survival effect of maximal cytoreductive surgery for advanced ovarian carcinoma during the platinum era: a meta-analysis. *J Clin Oncol* 2002;20:1248-59.
50. Young RC, Decker DG, Wharton JT, et al. Staging laparotomy in early ovarian cancer. *JAMA* 1983;250:3072-6.
51. Young RC, Walton LA, Ellenberg SS, et al. Adjuvant therapy in stage I and stage II epithelial ovarian cancer: results of two prospective randomized trials. *N Engl J Med* 1990;322:1021-7.
52. McGuire WP, Hoskins WJ, Brady MF, et al. Cyclophosphamide and cisplatin compared with paclitaxel and cisplatin in patients with stage III and stage IV ovarian cancer. *N Engl J Med* 1996;334:1-6.
53. Zaino RJ, Unger ER, Whitney C. Synchronous carcinomas of the uterine corpus and ovary. *Gynecol Oncol* 1984;19:329-35.
54. Omura GA, Brady MF, Homesley HD, et al. Long-term follow-up and prognostic factor analysis in advanced ovarian carcinoma: the Gynecologic Oncology Group experience. *J Clin Oncol* 1991;9:1138-50.
55. Kitazawa R, Kitazawa S, Maui T, Maeda S. In situ detection of parathyroid hormone-related protein in ovarian clear cell carcinoma. *Hum Pathol* 1997;28:379-82.
56. van der Burg ME, van Lent M, Buyse M, et al. The effect of debulking surgery after induction chemotherapy on the prognosis in advanced epithelial ovarian cancer. *N Engl J Med* 1995;332:629-34.
57. Rose PG, Nerenstone S, Brady M, et al. A phase III randomized study of interval secondary cytoreduction in patients with suboptimal residual disease: a Gynecologic Oncology Group Study. *Prog Proc Am Soc Clin Oncol* 2002;21:201a. abstract
58. Young RC. Early-stage ovarian cancer: to treat or not to treat. *J Natl Cancer Inst* 2003;95:94-5.
59. Colombo N, Chiari S, Maggioni A, Bocciarelli L, Torri V, Mangioni C. Controversial issues in the management of early epithelial ovarian cancer: conservative surgery and role of adjuvant therapy. *Gynecol Oncol* 1994;55:S47-S51.
60. Young RC, Brady MF, Nieberg RK, et al. Adjuvant treatment for early ovarian cancer: a randomized phase III trial of intraperitoneal 32P or intravenous cyclophosphamide and cisplatin — a Gynecologic Oncology Group study. *J Clin Oncol* 2003;21:4350-5.
61. Trimbs JB, Parmar M, Vergote I, et al. International Collaborative Ovarian Neoplasm trial 1 and Adjuvant ChemoTherapy In Ovarian Neoplasm trial: two parallel randomized phase III trials of adjuvant chemotherapy in patients with early-stage ovarian carcinoma. *J Natl Cancer Inst* 2003;95:105-12.
62. Bell J, Brady M, Lage JM, et al. A randomized phase III trial of three versus six cycles of carboplatin and paclitaxel as adjuvant treatment in early stage ovarian epithelial carcinoma: a Gynecologic Oncology Group study. *Gynecol Oncol* 2003;88:156.
63. Markman M. Informing patients with cancer of "new findings" that may influence their willingness to participate in research studies. *Cancer* 2003;98:885-7.
64. Rowinsky EK, Donehower RC. Paclitaxel (taxol). *N Engl J Med* 1995;332:1004-14. [Erratum, *N Engl J Med* 1995;333:75.]
65. Piccart MJ, Bertelsen K, James K, et al. Randomized intergroup trial of cisplatin-paclitaxel versus cisplatin-cyclophosphamide in women with advanced epithelial ovarian cancer: three-year results. *J Natl Cancer Inst* 2000;92:699-708.
66. International Collaborative Ovarian Neoplasm Group. Paclitaxel plus carboplatin versus standard chemotherapy with either single-agent carboplatin or cyclophosphamide, doxorubicin, and cisplatin in women with ovarian cancer: the ICON3 randomized trial. *Lancet* 2002;360:505-15. [Erratum, *Lancet* 2003;361:706.]
67. Ozols RE, Markman M, Thigpen JT. ICON3 and chemotherapy for ovarian cancer. *Lancet* 2002;360:2086-7.
68. Ozols RE, Bundy BN, Greer BE, et al. Phase III trial of carboplatin and paclitaxel compared with cisplatin and paclitaxel in patients with optimally resected stage III ovarian cancer: a Gynecologic Oncology Group study. *J Clin Oncol* 2003;21:3194-200.
69. du Bois A, Luck HJ, Meier W, et al. A randomized clinical trial of cisplatin/paclitaxel versus carboplatin/paclitaxel as first-line treatment of ovarian cancer. *J Natl Cancer Inst* 2003;95:1320-9.
70. Vasey PA. Survival and longer-term toxicity results of the SCOTROC study: docetaxel-carboplatin (DC) vs. paclitaxel-carboplatin (PC) in epithelial ovarian cancer (EOC). *Prog Proc Am Soc Clin Oncol* 2002;21:202a. abstract.
71. Lavin PT, Knapp RC, Malkasian G, Whitney CW, Berek JC, Bast RC Jr. CA 125 for the monitoring of ovarian carcinoma during primary therapy. *Obstet Gynecol* 1987;69:223-7.
72. Markman M, Lewis JL Jr, Saigo P, et al. Epithelial ovarian cancer in the elderly: the Memorial Sloan-Kettering Cancer Center experience. *Cancer* 1993;71:Suppl 2:634-7.
73. Crawford SM, Paul J, Reed NS, Hay A, Carty K, Vasey PA. The prognostic significance of the CA125 nadir in patients that achieve a CA125 response. *Prog Proc Am Soc Clin Oncol* 2004;23:448. abstract.
74. Ozols RE. Recurrent ovarian cancer: evidence-based treatment. *J Clin Oncol* 2002;20:1161-3.
75. Niloff JM, Knapp RC, Lavin PT, et al. The CA 125 assay as a predictor of clinical recurrence in epithelial ovarian cancer. *Am J Obstet Gynecol* 1986;155:56-60.
76. Markman M, Iseminger KA, Hatch KD, Creasman WT, Barnes W, Dubeshter B. Tamoxifen in platinum-refractory ovarian cancer: a Gynecologic Oncology Group Ancillary Report. *Gynecol Oncol* 1996;62:4-6.
77. Bowman A, Gabra H, Langdon SP, et al. CA125 response is associated with estrogen receptor expression in a phase II trial of letrozole in ovarian cancer: identification of an endocrine-sensitive subgroup. *Clin Cancer Res* 2002;8:2233-9.
78. Cannistra SA. Is there a "best" choice of second-line agent in the treatment of recurrent, potentially platinum-sensitive ovarian cancer? *J Clin Oncol* 2002;20:1158-60.
79. Markman M, Rothman R, Hakes T, et al. Second-line platinum therapy in patients with ovarian cancer previously treated with cisplatin. *J Clin Oncol* 1991;9:389-93.
80. Parmar MK, Ledermann JA, Colombo N, et al. Paclitaxel plus platinum-based chemotherapy versus conventional platinum-based chemotherapy in women with relapsed ovarian cancer: the ICON4/AGO-OVAR-2.2 trial. *Lancet* 2003;361:2099-106.
81. Pfisterer J, Plante M, Vergote I, et al. Gemcitabine/carboplatin (GC) vs. carboplatin (C) in platinum sensitive recurrent ovarian cancer (OVCA): results of a Gynecologic Cancer Intergroup randomized phase III trial of the AGO OVAR, the NCIC CTG and the EORTC GCG. *Prog Proc Am Soc Clin Oncol* 2004;23:449. abstract.
82. Hoskins WJ, Rubin SC, Dulancy E, et al. Influence of secondary cytoreduction at the

- time of second-look laparotomy on the survival of patients with epithelial ovarian carcinoma. *Gynecol Oncol* 1989;34:365-71.
83. Markman M. "Recurrence within 6 months of platinum therapy": an adequate definition of "platinum-refractory" ovarian cancer? *Gynecol Oncol* 1998;69:91-2.
84. Markman M, Kennedy A, Webster K, et al. Clinical features of hypersensitivity reactions to carboplatin. *J Clin Oncol* 1999;17:1141.
85. Ozols RF. The current role of gemcitabine in ovarian cancer. *Semin Oncol* 2001;28:18-24.
86. Markman M, Hall J, Spitz D, et al. Phase II trial of weekly single-agent paclitaxel in platinum/paclitaxel-refractory ovarian cancer. *J Clin Oncol* 2002;20:2365-9.
87. Homesley HD, Hall DJ, Martin DA, et al. A dose-escalating study of weekly bolus topotecan in previously treated ovarian cancer patients. *Gynecol Oncol* 2001;83:394-9.
88. Bookman MA, Malmstrom H, Bolis G, et al. Topotecan for the treatment of advanced epithelial ovarian cancer: an open-label phase II study in patients treated after prior chemotherapy that contained cisplatin or carboplatin and paclitaxel. *J Clin Oncol* 1998;16:3345-52.
89. Burger RA, DiSaia PJ, Roberts JA, et al. Phase II trial of vinorelbine in recurrent and progressive epithelial ovarian cancer. *Gynecol Oncol* 1999;72:148-53.
90. Gordon AN, Fleagle JT, Guthrie D, Parkin DE, Gore ME, Lacave AJ. Recurrent epithelial ovarian carcinoma: a randomized phase III study of pegylated liposomal doxorubicin versus topotecan. *J Clin Oncol* 2001;19:3312-22.
91. Skates SJ, Menon U, MacDonald N, et al. Calculation of the risk of ovarian cancer from serial CA-125 values for preclinical detection in postmenopausal women. *J Clin Oncol* 2003;21:Suppl:206s-210s.
92. Liotta LA, Kohn EC, Petricoin EF. Clinical proteomics: personalized molecular medicine. *JAMA* 2001;286:2211-4.
93. Bookman MA. Developmental chemotherapy and management of recurrent ovarian cancer. *J Clin Oncol* 2003;21:Suppl:149s-167s.
94. Berkenblit A, Tung N, Kim Y, et al. Phase I trial of docetaxel, carboplatin, and gemcitabine as first-line therapy for patients with high-risk epithelial tumors of müllerian origin. *Gynecol Oncol* 2003;89:486-93.
95. Alberts DS, Liu PY, Hannigan EV, et al. Intraperitoneal cisplatin plus intravenous cyclophosphamide versus intravenous cisplatin plus intravenous cyclophosphamide for stage III ovarian cancer. *N Engl J Med* 1996;335:1950-5.
96. Markman M, Bundy BN, Alberts DS, et al. Phase III trial of standard-dose intravenous cisplatin plus paclitaxel versus moderately high-dose carboplatin followed by intravenous paclitaxel and intraperitoneal cisplatin in small-volume stage III ovarian carcinoma: an intergroup study of the Gynecologic Oncology Group, Southwestern Oncology Group, and Eastern Cooperative Oncology Group. *J Clin Oncol* 2001;19:1001-7.
97. Armstrong DK, Bundy BN, Baergen R, et al. Randomized phase III study of intravenous (IV) paclitaxel and cisplatin versus IV paclitaxel, intraperitoneal (IP) cisplatin and IP paclitaxel in optimal stage III epithelial ovarian cancer (OC): a Gynecologic Oncology Group trial (GOG 172). *Prog Proc Am Soc Clin Oncol* 2002;21:201a. abstract.
98. Wenzel LB, Huang HM, Armstrong D, Walker J, Cella D. Quality of life (QOL) results of a randomized study of intravenous (IV) paclitaxel and cisplatin vs IV paclitaxel, intraperitoneal (IP) cisplatin, and IP paclitaxel in optimal stage III epithelial ovarian cancer (OC): a Gynecologic Oncology Group trial. *Prog Proc Am Soc Clin Oncol* 2004;23:454a. abstract.
99. Markman M, Liu PY, Wilczynski S, et al. Phase III randomized trial of 12 versus 3 months of maintenance paclitaxel in patients with advanced ovarian cancer after complete response to platinum and paclitaxel-based chemotherapy: a Southwest Oncology Group and Gynecologic Oncology Group trial. *J Clin Oncol* 2003;21:2460-5.
100. Ozols RF. Maintenance therapy in advanced ovarian cancer: progression-free survival and clinical benefit. *J Clin Oncol* 2003;21:2451-3.
101. Cannistra SA. The ethics of early stopping rules: who is protecting whom? *J Clin Oncol* 2004;22:1542-5.
102. Vasey PA, Shulman LN, Campos S, et al. Phase I trial of intraperitoneal injection of the E1B-55-kd-gene-deleted adenovirus ONYX-015 (dl1520) given on days 1 through 5 every 3 weeks in patients with recurrent/refractory epithelial ovarian cancer. *J Clin Oncol* 2002;20:1562-9.
103. Fang X, Schummer M, Mao M, et al. Lysophosphatidic acid is a bioactive mediator in ovarian cancer. *Biochim Biophys Acta* 2002;1582:257-64.
104. Reed JC. Dysregulation of apoptosis in cancer. *J Clin Oncol* 1999;17:2941-53.
105. Strobel T, Swanson L, Korsmeyer S, Cannistra SA. BAX enhances paclitaxel-induced apoptosis through a p53-independent pathway. *Proc Natl Acad Sci U S A* 1996;93:14094-9.
106. Alper O, Bergmann-Leitner ES, Bennett TA, Hacker NE, Stromberg K, Stetler-Stevenson WG. Epidermal growth factor receptor signaling and the invasive phenotype of ovarian carcinoma cells. *J Natl Cancer Inst* 2001;93:1375-84.
107. Abu-Jawdeh GM, Faix JD, Niloff J, et al. Strong expression of vascular permeability factor (vascular endothelial growth factor) and its receptors in ovarian borderline and malignant neoplasms. *Lab Invest* 1996;74:1105-15.
108. Berkenblit A, Cannistra SA. Biologic and clinical implications of vascular endothelial growth factor expression in ovarian cancer. *Women's Oncol Rev* 2001;1:1-8.
109. Mendelsohn J. Targeting the epidermal growth factor receptor for cancer therapy. *J Clin Oncol* 2002;20:Suppl:1S-13S.
110. Spentzos D, Levine DA, Ramoni MF, et al. A gene expression profile with independent prognostic significance in epithelial ovarian cancer. *J Clin Oncol* (in press).

Copyright © 2004 Massachusetts Medical Society.