J Gastrointest Surg (2012) 16:1406–1411
DOI 10.1007/s11605-012-1877-7

HOW I DO IT

How I Do It: Laparoscopic Paraesophageal Hernia Repair

Edward D. Auyang · Carlos A. Pellegrini

Received: 7 February 2012 / Accepted: 20 March 2012 / Published online: 12 April 2012
© 2012 The Society for Surgery of the Alimentary Tract

Abstract
Introduction Paraesophageal hernias are usually complex anatomic abnormalities of the upper gastrointestinal tract capable of causing symptoms and complications including death. Furthermore, they affect patients who are usually older and have other comorbidities. Preferred treatment approach has evolved over time, with laparoscopic repair being the current preferred technique as it causes less hemodynamic changes and is better tolerated than open repairs.
Technique In this report, we describe our technique for laparoscopic paraesophageal hernia repair. The most salient technical aspects of this procedure include reduction of the stomach below the diaphragm, circumferential dissection and excision of the hernia sac, closure of the crural defect with our without the addition of mesh, and fundoplication to prevent reflux.
Conclusion While this procedure has a low morbidity risk and short hospital stay, anatomic recurrence is frequent even when performed by experienced surgeons.

Keywords Paraesophageal hernia repair · Hiatal hernia · Antireflux procedure · Biologic mesh · Esophageal lengthening

Introduction

Hiatal hernias were first described by Henry Ingersoll Bowditch, a physician at the Massachusetts General Hospital, in 1853.[1] He identified a special type of hiatal hernias, characterized by an esophagus that "turned back" through the diaphragm "to join the stomach in the chest." Paraesophageal hernias (PEHs) were later identified as a subtype of hiatal hernias by Swedish radiologist Ake Akerlund in 1926.[2] Surgical technique for repair of PEHs has evolved from the abdominal to thoracic approaches and, over the last 20 years, to a laparoscopic approach. In this report, we describe in detail how we perform the laparoscopic paraesophageal hernia repair.

E. D. Auyang · C. A. Pellegrini (✉)
Department of Surgery, University of Washington,
1959 NE Pacific Street, Box 356410, Seattle, WA 98195, USA
e-mail: pellegri@u.washington.edu

Preoperative Planning

Patients who have symptomatic paraesophageal hernias (frequent postprandial discomfort and/or vomiting, chronic anemia, ulcerations, symptoms of reflux) and who can withstand an operative procedure under general anesthesia safely are offered a surgical repair.[3] Preoperatively, patients undergo barium esophagogram to confirm the diagnosis of PEH and define the anatomy of the esophagus, stomach, and gastroesophageal junction (GEJ). Additionally, all patients have upper endoscopy to look for ulcerations and erosions and to rule out the presence of neoplasms. Esophageal manometry is routinely performed to assess esophageal peristalsis and lower esophageal sphincter function. While the results seldom change operative decision making, there are rare occasions when severe esophageal dysmotility alters the decision to perform a complete fundoplication. Additionally, 24-h pH monitoring is performed for patients with gastroesophageal reflux symptoms to determine the magnitude of reflux.

Technique

Patients are instructed to be NPO after midnight the day before the operation. We routinely administer preoperative

subcutaneous heparin for deep vein thrombosis prophylaxis and administer a first-generation cephalosporin or equivalent for antibiotic prophylaxis within an hour prior to the start of the operation. The patient is positioned on the OR table on top of a bean bag. An upper-body warming device and bilateral lower extremity sequential compression devices are applied. We routinely place a Foley catheter given that most of these operations last more than 2 h. General anesthesia is induced, and the patient is placed in stirrups in a low lithotomy position. The bean bag is evacuated and forms a "seat," thus preventing slipping when the patient is in complete reverse Trendelenburg position. Additionally, both arms are tucked, and a safety strap is placed on the patient's lower legs or thighs. We prefer to tuck both arms to allow for placement of a self-retaining retractor by the patient's right arm and to allow for the assistant to stand closely on the patient's left. The surgeon subsequently stands between the legs. The laparoscopic monitor is placed in the midline directly over the patient's upper chest for direct viewing.

Pneumoperitoneum is obtained using a Veress needle technique typically at the left subcostal margin. Our preference, for safety reasons, is to place the first trocar under direct vision. To that end, we use an 11-mm bladed optical trocar (Visiport Plus RPF, Covidien, Norwalk, CT) placed in this left subcostal location (Fig. 1). A 10-mm trocar is placed at a left supraumbilical location approximately one hand-width below and medial to the left subcostal port. A 5-mm left flank assistant port and a 5-mm right subcostal working port are then placed. Finally, either a Nathanson retractor (Nathanson Large Hook, Mediflex, Islandia, NY) is placed at a subxiphoid location without a port, or for patients with a large liver, a paddle liver retractor (Endo Paddle Retract, Covidien, Norwalk, CT) is placed through a right flank 11-mm port site. The liver retractor is held in place with a self-retaining retractor (StrongArm, Mediflex, Islandia, NY) affixed to the right side of the OR table and positioned at the level of the patient's right axilla. The patient is then placed in steep reverse Trendelenburg position.

As we start the operation, it is our practice to try to reduce the contents of the hernia as much as possible. In doing so, it is not infrequent to find a portion of the colon or a fair amount of omentum herniated through the diaphragm, which can be easily reduced into the abdomen. We then try to reduce the stomach with very gentle traction to avoid tearing the surface of the organ. In some instances, smaller hernias, the entire stomach can be reduced, and the process is greatly facilitated (Fig. 2). More often, however, only a partial reduction can be achieved. In these patients, we start the dissection by dividing the sac along the left crus of the diaphragm or start by dividing the short gastric vessels,

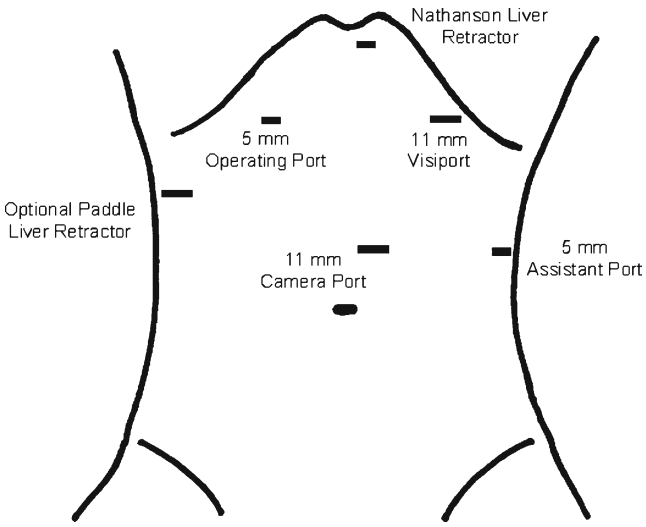

Fig. 1 Port placement for laparoscopic paraesophageal hernia repair

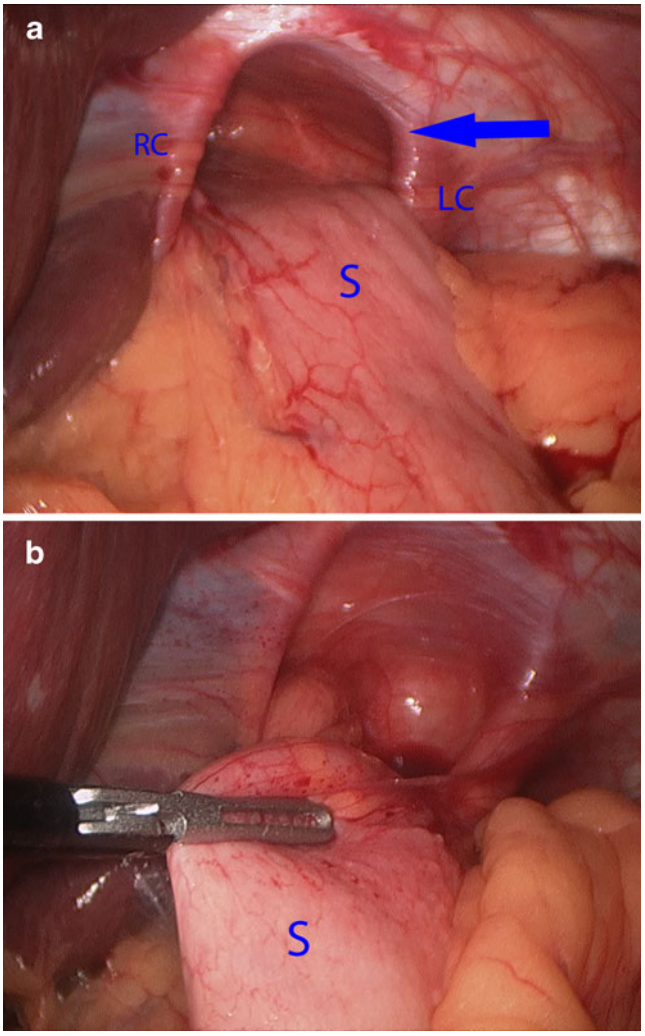

Fig. 2 **a** Paraesophageal hernia (*arrow* points to hernia, *S* stomach, *LC* left crus, *RC* right crus). **b** Reduced stomach (*S* stomach)

depending on what appears easier. In these cases, traction is placed on the greater curve of the stomach, and the short gastric arteries are divided using a bipolar or ultrasonic energy device (LigaSure 5 mm, Covidien, Boulder, CO or AutoSonix Ultra Shears, Covidien, Norwalk, CT). The arteries are divided for a distance of 1/3 of the superior greater curve. Once the left crus is reached (or in cases in which the stomach was completely reduced, earlier), the avascular fibroareolar plane between the hernia sac and the medial border of the crus is entered. Properly identifying and dissecting in this plane makes clearer delineation of the mediastinal structures. The left mediastinal pleura is usually evident and gently dissected outwards and away from the sac using blunt dissection. In most instances at this stage, carbon dioxide (CO_2) insufflation facilitates further separation of the sac from the pleura and allows the entire sac on the left side to progressively come down. In these patients, we transition slowly to the anterior aspect (the "virtual" space between the pericardium and the anterior aspect of the sac). If the deep border of the hernia sac is not reached, if it does not come down safely, or if it is intimately adherent to the undersurface of the aortic arch, the sac is divided leaving the top in the mediastinum deeply buried, which may increase the risk of recurrence.[4, 5] Otherwise, the hernia sac is completely dissected in a counterclockwise fashion, coming on to the right side and separating it from the pericardium paying close attention to avoid injuring the pleura and the anterior vagus nerve. The insertion of the sac on the right crus is treated in a similar fashion—the space is entered in this area, and one can usually make their way to join the area that has been dissected from the left side completing the right, anterior, and left side dissection (Fig. 3). The dissection on the right side is usually more difficult than on the left. The left gastric artery is frequently "pulled" up into the mediastinum as the hernia develops and grows, and care must be taken to avoid damaging it. Eventually, we turn to the posterior sac, carefully watching for the posterior vagus nerve. This is performed until both sides are joined and a superficial circumferential dissection is completed. A Penrose drain placed at the level of the GEJ helps provide traction on the esophagus and reduction of the stomach. Using a combination of blunt dissection, electrocautery, and energy devices, the circumferential dissection is performed high into the mediastinum in order to completely reduce the hernia (Fig. 4). The hernia sac is then completely excised from the GE junction to reduce the chance of recurrence and to clearly expose both crura for the hiatal closure.

Closure of the hiatus can be challenging due to the attenuation of the muscle. A tension-free closure of the hiatus is best, but it is rarely possible (Fig. 5). In most instances, there is tension on the closure, and one has to be careful not to tear, particularly the right crus. If this starts occurring, the easiest way to deal with the situation is to close the hiatus anterior to the esophagus, and if this is not possible, a relaxing incision on the right crus—away from its edges—is performed to facilitate closure. Hiatal closure is performed using interrupted 2-0 silk sutures posterior to the esophagus. Occasionally, anterior hiatal stitches are placed to prevent overangulation by too many posterior sutures. The hiatal closure has to be tested, as the view does not provide a sense of the tightness. We gauge its tightness using a 52-French bougie that is passed transorally with the tip guided into the gastric body. If there is difficulty obtaining a tension-free repair, we will perform a relaxing incision on the diaphragm just anterolateral to the right crus. Subsequently, we place a U-shaped biologic mesh to cover this defect and to buttress the crural repair. For higher tension repairs in which a

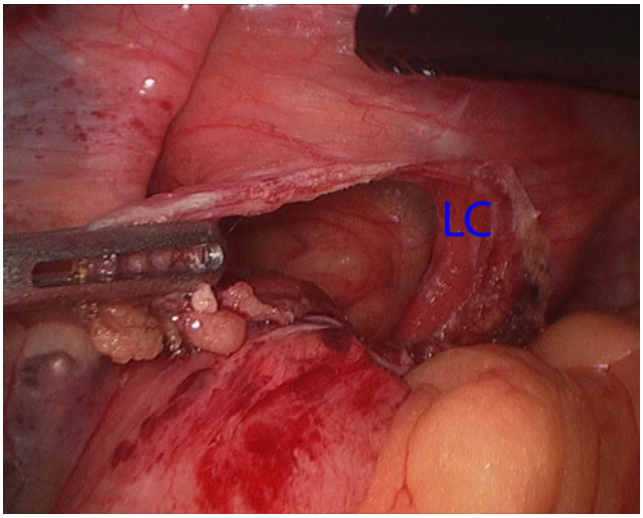

Fig. 3 Dissection of left crus (*LC*)

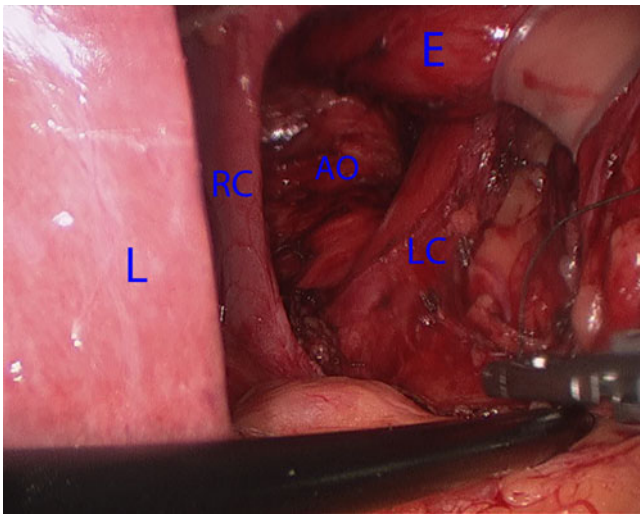

Fig. 4 Circumferential dissection of the hernia (*LC* left crus, *RC* right crus, *E* esophagus, *AO* aorta, *L* liver)

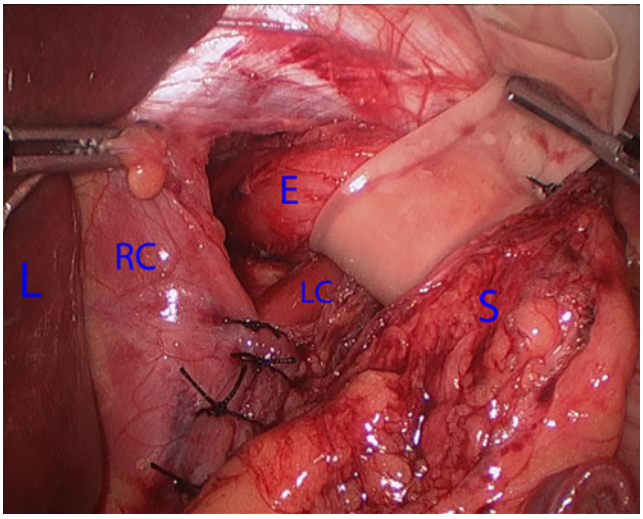

Fig. 5 Crural closure (*LC* left crus, *RC* right crus, *E* esophagus, *L* liver, *S* Stomach)

relaxing incision is not used, we are selectively placing a biologic mesh. A U-shaped small intestine submucosa mesh (Biodesign/Surgisis, Cook Medical, Bloomington, IN), is sutured to the diaphragm at two points on the anterior leaflets and affixed to the diaphragm with fibrin glue (Fig. 6).

A floppy Nissen fundoplication is routinely performed on our patients with PEH given that the majority of the patients have reflux symptoms, and even if the patient does not have reflux symptoms preoperatively, the large dissection and mobilization required may bring about reflux postoperatively.[6] Additionally, the fundoplication can be used as a "gastropexy" to the inferior aspect of the hiatus.[7] To perform the fundoplication, a marking stitch is placed on the posterior fundus 3 cm inferior to the GEJ and 3 cm medial to the greater curve of the stomach. The posterior fundus is passed posterior to the esophagus, and a mirror location on the anterior fundus is grasped and brought together to it. The fundoplication is inspected and repositioned to reduce any redundancy. A "shoeshine" maneuver is performed to assess free mobilization of the fundus, and a 3-cm wrap is constructed with four interrupted permanent sutures over a 52-French bougie. Next, the fundoplication is sutured to the esophagus and below the diaphragm in three locations to help reduce recurrence (Fig. 7). The first pexy suture is placed from the right superior aspect of the fundoplication, through the right lateral esophagus, to the midpoint of the medial edge of the right crus (9 o'clock stitch). The second suture is placed from the medial edge of the left crus, to the left anterolateral esophagus, to the superior edge of the left side of the fundoplication (3 o'clock stitch). The third suture is placed on the left superior aspect of the fundoplication at a midpoint between the first two sutures and attached to the anterior right crus (11 o'clock stitch). The sutures placed in these three locations help prevent twisting of the fundoplication and stabilize the wrap in a normal

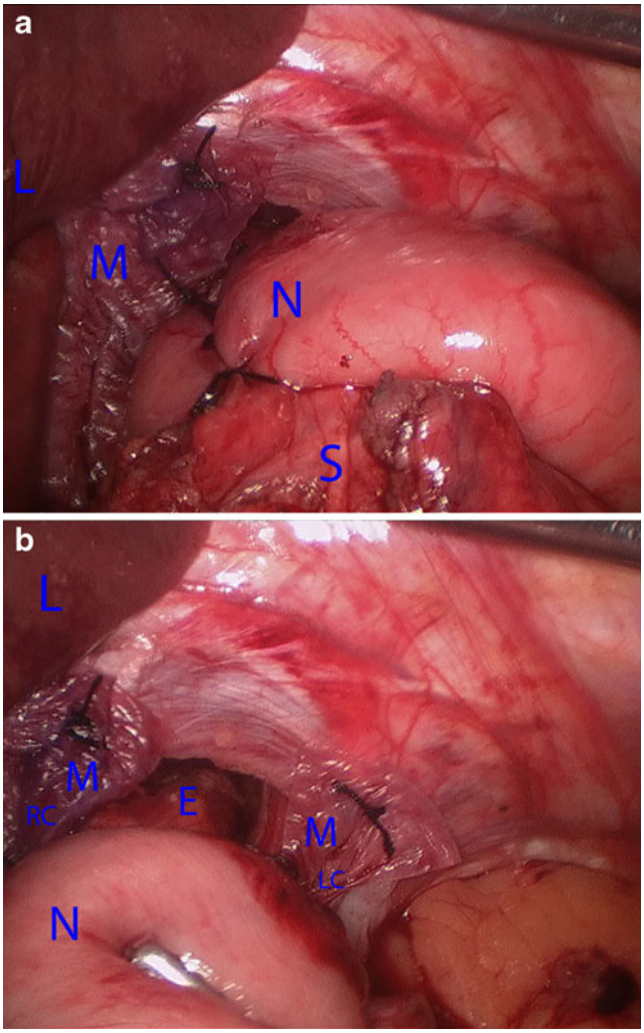

Fig. 6 **a**, **b** Placement of mesh for the crural closure (*M* mesh, *S* stomach, *L* liver, *LC* left crus, *RC* right crus, *E* esophagus, *N* nissen fundoplication)

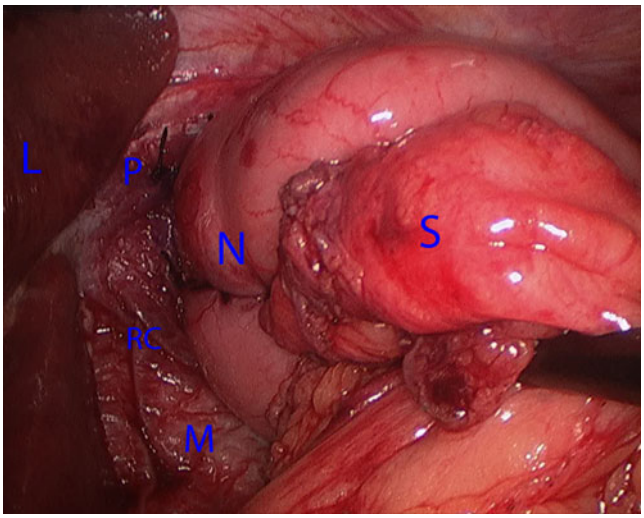

Fig. 7 Creation of Nissen fundoplication and pexy to the diaphragm (*N* Nissen, *P* pexy stitch, *S* stomach, *RC* right crus, *L* liver, *M* mesh)

orientation. In the rare case when preoperative manometry identifies a very severe esophageal dysmotility disorder (90 % or more failed peristaltic contractions), a 270° fundoplication such as a Toupet or Dor will be performed as an alternative to avoid creating a functional obstruction. Prior to removal of the ports and closure of the port sites, all patients undergo an intraoperative upper endoscopy to confirm repair of the PEH, normal untwisted orientation of the stomach, and appropriate creation of the fundoplication.

Patients are admitted overnight for observation. A clear liquid diet is started the day of surgery and advanced to soft on postoperative day 1. A clinical nutritionist meets with the patient prior to discharge to review instructions on gradually advancing their diet over a 6-week period. They are instructed to specifically avoid foods that have a tendency to get stuck in the distal esophagus causing retching such as bread, meat, and vegetables. Most patients are discharged home on postoperative day 1 and seen at 2–3 weeks and 6 months for routine follow-up. The 6-month follow-up includes readministration of a symptom questionnaire and repeat upper GI barium swallow to evaluate the anatomy of the repair. If patients have symptoms of reflux or dysphagia, pH and/or manometry testing is repeated at this time as well.

Discussion

Laparoscopic paraesophageal hernia repair requires advanced laparoscopic experience, but with that experience, the procedure is safe and effective. Long-term studies have shown low mortality and morbidity rates, even in patients with advanced age or associated comorbidities.[8] Despite the effectiveness of the procedure, there is still a high recurrence rate.[9, 10]

There is a debate whether biologic mesh will reduce recurrence if used to buttress the crural repair. A multicenter prospective randomized study showed that a biologic mesh (Biodesign/Surgisis, Cook Medical, Bloomington, IN) decreased recurrence rates at 6 months from 24 % in primary closures to 9 % in mesh closures.[11] Interestingly, the long-term follow-up of this study was recently published and showed that the recurrence rate at 5 years was high (slightly above 50 %) for both types of repairs and that the small differences observed were not significant.[12] Several hypotheses exist to explain the difference in short- and long-term recurrence. It is possible, for example, that since the mesh is absorbed in about 6 months, that the extra strength provided by its application disappears with time. Permanent meshes have been advocated by some surgeons, but we do not use or recommend them because they tend to cause erosion, obstruction, and other complications.[13] While further investigations continue, our practice is to selectively use biologic mesh to buttress the crural repair depending on the amount of tension on the primary closure.

Another debated cause of recurrence is the presence of a shortened esophagus. It had been hypothesized that a shortened esophagus causes axial tension on the fundoplication, resulting in enhancing the chances of recurrence of the hiatal hernia. Esophageal lengthening procedures, specifically Collis gastroplasty, have been advocated for patients who have a shortened esophagus.[14] Extended mediastinal dissection was identified as an alternative to Collis to increase intra-abdominal esophageal length.[15] Vagotomy has also been identified as a method to lengthen the esophagus, and at least one report showed that it was not associated with other side effects usually attributed to vagotomy.[16] The preferred approach is still greatly debated. Several experienced centers have modified their practice showing decreased recurrence rates over time by utilizing both extended mediastinal dissection as well as more liberal use of Collis gastroplasty.[17, 18] Our practice has been to perform high extended mediastinal dissections for esophageal lengthening. We have reserved Collis gastroplasty or vagotomy for rare cases when the gastroesophageal junction fails to reach the abdomen despite extensive mediastinal dissections.

Conclusions

Paraesophageal hernias are difficult surgical problems. Laparoscopic paraesophageal hernia repair is a feasible and safe procedure in experienced hands, but despite the use of adjuncts such as biologic mesh and modified techniques for esophageal lengthening, long-term recurrence rates are still high even when performed by experienced surgeons.

References

1. Bowditch HI. A treatise on diaphragmatic hernia. Buffalo: Jewett, Thomas & Co.; 1853.
2. Stylopoulos N, Rattner DW. The history of hiatal hernia surgery. Ann Surg 2005; 241: 185–193.
3. Stylopoulos N, Gazelle S, Rattner DW. Paraesophageal hernias: operation or observation? Ann Surg 2002; 236(4): 492–501.
4. Edye M, Salky B, Posner A, Fierer A. Sac excision is essential to adequate laparoscopic repair of paraesophageal hernia. Surg Endosc 1998; 12(10): 1259–63.
5. Watson DL, Davies N, Devitt PG, Jamieson GG. Importance of dissection of the hernia sac in laparoscopic surgery for large hiatal hernias. Ann Surg 1999; 134:1069–1073.
6. Casabella F, Sinanan M, Horgan S, Pellegrini CA. Systematic use of gastric fundoplication in laparoscopic repair of paraesophageal hernias. Am J Surg 1996; 171(5):485–489.
7. Horgan S, Eubanks TR, Jacobsen G, Omelanczuk P, Pellegrini CA. Repair of paraesophageal hernias. Am J Surg 1999; 177(5):354–358.
8. Gangopadhyay N, Perrone JM, Soper NJ, Matthews BD, Eagon JC, Klingensmith ME, Frisella MM, Brunt LM. Outcomes of

laparoscopic paraesophageal hernia repair in elderly and high-risk patients. Surgery 2006; 140:491–9.
9. Mattar SG, Bowers SP, Galloway KD, Hunter JG, Smith CD. Long-term outcome of laparoscopic repair of paraesophageal hernia. Surg Endosc 2002; 16:745–9.
10. Pierre AF, Luketich JD, Fernando HC, Christie NA, Buenaventura PO, Litle VR, et al. Results of laparoscopic repair of giant paraesophageal hernias: 200 consecutive patients. Ann Thor Surg 2002; 74:1909–15.
11. Oelschlager BK, Pellegrini CA, Hunter JG, Soper NJ, Brunt ML, Sheppard BC, Jobe B, Polissar NL, Mitsumori LM, Nelson J, Swanstrom LL. Biologic prosthesis reduces recurrence after laparoscopic paraesophageal hernia repair: a multicenter, prospective, randomized trial. Ann Surg 2006; 244:481–490.
12. Oelschlager BK, Pellegrini CA, Hunter JG, Brunt ML, Soper NJ, Sheppard BC, Polissar NL, Neradilek MB, Mitsumori LM, Rohrmann CA, Swanstrom LL. Biologic prosthesis to prevent recurrence after laparoscopic paraesophageal hernia repair: long-term follow-up from a multicenter, prospective, randomized trial. JACS 2011; 213:461–468.
13. Tatum RP, Shalhub S, Oelschlager BK, Pellegrini CA. Complications of PTFE mesh at the diaphragmatic hiatus. J Gastrointest Surg 2008; 12:953–957.
14. Swanstrom LL, Marcus DR, Galloway GQ. Laparoscopic Collis gastroplasty is the treatment of choice for the shortened esophagus. Am J Surg 1996; 171(5): 477–81.
15. O'Rourke RW, Khajanchee YS, Urbach DR, Lee NN, Lockhart B, Hansen PD, Swanstrom LL. Extended transmediastinal dissection: an alternative to gastroplasty for short esophagus. Arch Surg 2003; 138(7): 735–40.
16. Oelschlager BK, Yamamoto K, Woltman T, Pellegrini C. Vagotomy during hiatal hernia repair: a benign esophageal lengthening procedure. J Gastrointest Surg 2008; 12: 1155–1162.
17. Luketich JD, Nason KS, Christie NA, Pennathur A, Jobe BA, Landreneau RJ, Schuchert MJ. Outcomes after a decade of laparoscopic giant paraesophageal hernia repair. J Thorac Cardiovasc Surg 2010; 139(2): 395–404.
18. Zehetner J, DeMeester SR, Ayazi S, Kilday P, Augustin F, Hagen JA, Lipham JC, Sohn HJ, DeMeester TR. Laparoscopic versus open repair of paraesophageal hernia: the second decade. JACS 2011; 212:813–820.