

Diagnosis and Initial Management of Nonmalignant Diseases Related to Asbestos

THIS OFFICIAL STATEMENT OF THE AMERICAN THORACIC SOCIETY WAS ADOPTED BY THE ATS BOARD OF DIRECTORS ON DECEMBER 12, 2003

CONTENTS

- Diagnostic Criteria and Guidelines for Documenting Them
 - Asbestos as a Hazard
 - Asbestos in Lung Tissue
- Clinical Evaluation and Indicators
 - Symptoms
 - Occupational and Environmental History
 - Physical Examination
 - Conventional Imaging
 - Computed Tomography
 - Bronchoalveolar Lavage
 - Pulmonary Function Tests
- Nonmalignant Disease Outcomes
 - Asbestosis
 - Nonmalignant Pleural Abnormalities Associated with Asbestos
 - Chronic Airway Obstruction
- Implications of Diagnosis for Patient Management
 - Actions Required before Disease Is Apparent
 - Actions Required after Diagnosis
- Conclusions

Asbestos is a general term for a heterogeneous group of hydrated magnesium silicate minerals that have in common a tendency to separate into fibers (1). These fibers, inhaled and displaced by various means to lung tissue, can cause a spectrum of diseases including cancer and disorders related to inflammation and fibrosis. Asbestos has been the largest single cause of occupational cancer in the United States and a significant cause of disease and disability from nonmalignant disease. To this demonstrable burden of asbestos-related disease is added the burden of public concern and fear regarding risk after minimal exposure.

This statement presents guidance for the diagnosis of nonmalignant asbestos-related disease. Nonmalignant asbestos-related disease refers to the following conditions: asbestosis, pleural thickening or asbestos-related pleural fibrosis (plaques or diffuse fibrosis), "benign" (nonmalignant) pleural effusion, and airflow obstruction. This document is intended to assist the clinician in making a diagnosis that will be the basis for individual management of the patient. It therefore provides overarching criteria for the diagnosis, specific guidelines for satisfying these criteria, and descriptions of the clinical implications of the diagnosis, including the basic management plan that should be triggered by the diagnosis. It is understood that disease may be present

at a subclinical level and may not be sufficiently advanced to be apparent on histology, imaging, or functional studies.

One of the most important implications of the diagnosis of nonmalignant asbestos-related disease is that there is a close correlation between the presence of nonmalignant disease and the risk of malignancy, which may arise from exposure levels required to produce nonmalignant disease or mechanisms shared with premalignant processes that lead to cancer. The major malignancies associated with asbestos are cancer of the lung (with a complex relationship to cigarette smoking) and mesothelioma (pleural or peritoneal), with excess risk also reported for other sites. There is a strong statistical association between asbestos-related disease and malignancy, but the majority of patients with nonmalignant asbestos-related disease do not develop cancer. On the other hand, the risk of cancer may be elevated in a person exposed to asbestos without obvious signs of nonmalignant asbestos-related disease. However, a diagnosis of nonmalignant asbestos-related disease does imply a lifelong elevated risk for asbestos-related cancer.

DIAGNOSTIC CRITERIA AND GUIDELINES FOR DOCUMENTING THEM

People with past exposure to asbestos consult physicians for many relevant reasons: to be screened for asbestos-related disease, for evaluation of specific symptoms that may relate to past asbestos exposure (known or unsuspected), for treatment and advice, and for evaluation of impairment. In 1986, the American Thoracic Society convened a group of experts to review the literature and to present an authoritative consensus view of the current state of knowledge with respect to diagnosis of nonmalignant disease related to asbestos (2). In 2001, a new group was convened to review and to update the 1986 criteria. This statement constitutes that committee's report, completed in 2004.

The criteria formulated in this statement are intended for the diagnosis of nonmalignant asbestos-related disease in an individual in a clinical setting for the purpose of managing that person's current condition and future health. These general criteria are slightly modified from those presented in 1986 (Table 1) (2):

- Evidence of structural pathology consistent with asbestos-related disease as documented by imaging or histology
- Evidence of causation by asbestos as documented by the occupational and environmental history, markers of exposure (usually pleural plaques), recovery of asbestos bodies, or other means
- Exclusion of alternative plausible causes for the findings

The rest of this statement is largely devoted to presenting clinical guidelines required to document that each of these criteria is met. Demonstration of functional impairment is not required for the diagnosis of a nonmalignant asbestos-related disease, but where present should be documented as part of the complete evaluation. Evaluation of impairment has been exten-

Members of the Ad Hoc Statement Committee have disclosed any direct commercial associations (financial relationships or legal obligations) related to the preparation of this statement. This information is kept on file at the ATS headquarters.

TABLE 1. CRITERIA FOR DIAGNOSIS OF NONMALIGNANT LUNG DISEASE RELATED TO ASBESTOS

1986 Guidelines	2004 Guidelines	Comparison and Notes
Chest film (irregular opacities)	Evidence of structural change, as demonstrated by one or more of the following: • Imaging methods	Demonstrates the existence of a structural lesion consistent with the effects of asbestos. The criteria outlined in the 1986 guidelines were most explicit for asbestosis Chest film, HRCT, and possibly future methods based on imaging. The 1986 guidelines specified ILO classification 1/1
Pathology (College of American Pathologists)	• Histology (College of American Pathologists)	Criteria for identifying asbestosis on microscopic examination of tissue are unchanged
Consistent time interval	Evidence of plausible causation, as demonstrated by one or more of the following:	Evidence of plausible causation implies that the temporal relationship, including latency, is plausible
Occupational and environmental history	• Occupational and environmental history of exposure (with plausible latency) • Markers of exposure (e.g., pleural plaques)	
Asbestos bodies or fibers in lung tissue	• Recovery of asbestos bodies	The 2004 guidelines are not limited to lung tissue, consider the role of BAL to be established, and deemphasize fibers because they are difficult to detect and a systematic analysis for asbestos fibers is not generally available
Rule out other causes of interstitial fibrosis or obstructive disease	Exclusion of alternative diagnoses	The 1986 guidelines primarily addressed asbestosis but mentioned smoking as a cause of obstructive disease. Implicit in the article, however, is that nonmalignant diseases presenting similarly to asbestos-related disease should also be ruled out
“Evidence of abnormal test”	Evidence of functional impairment, as demonstrated by one or more of the following:	Functional assessment is not required for diagnosis but is part of a complete evaluation. It contributes to diagnosis in defining the activity of disease and the resulting impairment
Crackles, bilateral, not cleared by cough	• Signs and symptoms (including crackles)	Signs and symptoms are not specific for diagnosis but are valuable in assessing impairment
Restrictive disease	• Change in ventilatory function (restrictive, obstructive patterns in context or disease history)	The 1986 criteria admitted the possibility of obstructive disease; the 2004 criteria address this specifically
Reduced diffusing capacity	• Impaired gas exchange (e.g., reduced diffusing capacity) • Inflammation (e.g., by bronchoalveolar lavage)	
	• Exercise testing	The 1986 guidelines noted possible utility of bronchoalveolar lavage and gallium scanning but considered them to be experimental techniques. The 2004 guidelines exclude gallium scanning, suggest that additional indicators of active inflammation may become useful in future

Definition of abbreviations: BAL = bronchoalveolar lavage; HRCT = high-resolution computed tomography; ILO = International Labour Organization. From References 64 and 65.

sively reviewed elsewhere and is not repeated here (3). Functional impairment may be demonstrated by evidence of symptoms or signs, ventilatory dysfunction, impaired gas exchange, and inflammation. Pulmonary function testing should be conducted in conformity with standards already published by the American Thoracic Society (4, 5), including multiple trials to confirm reproducibility and documentation of all trials attempted.

These guidelines are designed for clinical application, not for research, epidemiologic surveillance, screening, litigation, or adjudication. They balance the need to be as accurate as possible with protection of the patient's safety and the yield, cost, and accessibility of the diagnostic procedures available. These guidelines, if they err, err on the side of specificity rather than sensitivity. This is because nonmalignant asbestos-related disorders are difficult to detect in their earliest stages and because there is no early intervention that has been proven to alter the subsequent evolution of the disease. On the other hand, the documentation of causation by asbestos carries important implications for the patient and can be established with reasonable certainty, once the disease is identified.

Asbestos as a Hazard

The generic term “asbestos” is used to describe a group of minerals that, when crushed, break into fibers. As defined by

the National Research Council (1), the term “asbestos” is a “commercial-industrial term rather than a mineralogical term. It refers to well-developed and hair-like long-fibered varieties of certain minerals that satisfy particular industrial needs.” They are chemically heterogeneous hydrated silicates and each has chemical analogs with different structures that do not form fibers. Fibers have parallel sides with length three or more times greater than width. Asbestos fibers have great tensile strength, heat resistance, and acid resistance; varieties are also flexible. The six minerals that are traditionally defined as asbestos include chrysotile asbestos (the asbestiform variety of serpentine); the amphiboles, which include crocidolite (the asbestiform variety of riebeckite) and amosite (the asbestiform variety of cummingtonite-grunerite); and the asbestiform varieties of the amphiboles, which include anthophyllite (anthophyllite asbestos), actinolite (actinolite asbestos), and tremolite (tremolite asbestos) (6). Just as all forms of asbestos, by the definition and classification above, appear to cause malignancy, all may cause the non-malignant diseases described. Issues of relative potency among the forms of asbestos, and particularly between chrysotile and the amphiboles, are primarily of concern with respect to the risk of malignancy and are not discussed in this document.

Commercial-grade asbestos is made up of fiber bundles. These bundles, in turn, are composed of extremely long and thin fibers, often with splayed ends, that can easily be separated from

one another. Commercial asbestos has high tensile strength, flexibility, resistance to chemical and thermal degradation, and high electrical resistance, and can often be woven. On the basis of these characteristics, asbestos was broadly used in the past in insulation, brake linings, flooring, cement, paint, textiles, and many other products; however, commercial use has declined substantially in more recent years.

Asbestos and asbestiform minerals may occur as a natural accessory mineral in other industrial mineral deposits or rocks. These asbestiform amphiboles and some other fibrous minerals may not completely fit the commercial definition of asbestos but may have similar effects, such as the tremolite-like asbestiform mineral found in association with vermiculite in Libby, Montana (7). Although the general criteria still apply, the specific diagnostic guidelines provided in this statement may or may not apply in such situations, depending on the mineral and exposure circumstances. Documentation of health effects in the scientific literature for these minerals is not as extensive as for chrysotile and the common amphiboles.

World production and use of asbestos climbed steadily since its commercial introduction in the late nineteenth century and fell rapidly after documentation of its hazards in the 1970s and 1980s. In Western industrialized countries, the widespread use of asbestos in industry and in the built environment in the first seven decades of the twentieth century has resulted in an epidemic of asbestos-related illness that now continues into the twenty-first century, despite decline in global production and use. Its use has now been banned in many Western countries. Asbestos is still mined in Russia and China, mainly for local use, and in Canada, where most of the product is exported to Asia and Africa.

Today, with stringent regulation of asbestos use and the disappearance of almost all asbestos-containing products from the market, nonmalignant asbestos-related disease is primarily a concern in four settings in the developed world: (1) the historical legacy of asbestos exposure affecting older workers; (2) the current risk experienced by the workforce engaged in certain occupations managing the remaining hazard, such as building and facility maintenance; (3) asbestos abatement operations, removing insulation and other asbestos-containing products; and (4) renovation and demolition of structures containing asbestos. In the developing world, workers and their families continue to be exposed. In some countries, including industrialized countries formerly belonging to the Eastern bloc and rapidly industrializing countries in Asia, the use of asbestos continues and may even be increasing.

Asbestos is still a hazard for an estimated 1.3 million workers in the construction industry in the United States and for workers involved in maintenance of buildings and equipment (8). Most asbestos in the United States today exists in building and machinery insulation and old products, such as appliances, that may be available for resale. New products that may contain asbestos today in the United States include friction surfaces (brake pads), roofing materials, vinyl tile, and imported cement pipe and sheeting. Significant asbestos content may be present as a contaminant in vermiculite insulation often found in homes (7).

Historically, occupations at greatest risk for nonmalignant asbestos-related disease have tended to be those engaged in the production and end use of products made from asbestos. These have included a wide assortment of items, including friction pads, brake linings, gas masks, cement water pipe, insulation, and textiles. Occupations engaged in the mining and extraction of asbestos have usually shown lower frequencies of nonmalignant asbestos-related disease. Passive exposure, including workers carrying home asbestos on their clothing, was historically associated with elevated cancer risk, particularly mesothelioma, and

risk of nonmalignant asbestos-related disease. Workers in building and equipment maintenance may still encounter asbestos insulation even though asbestos is no longer widely used in commerce. Asbestos abatement activities, including removal and replacement of insulation, provide opportunities for exposure among contemporary workers (8).

Asbestos in Lung Tissue

Asbestos fibers carried to the deep lung induce an alveolitis that results in fibrosis. Inhaled asbestos fibers can also result in pleural inflammation. Asbestos fibers are transported to the pleural surface along lymphatic channels by macrophages and/or by direct penetration. The degree of fibrosis in asbestosis is dose dependent (9–12).

Asbestos fibers are deposited at airway bifurcations and in respiratory bronchioles and alveoli primarily by impaction and interception. Fibers migrate into the interstitium, in part via an uptake process involving Type I alveolar epithelial cells. This causes an alveolar macrophage-dominated alveolitis, as demonstrated in Figure 1 (12, 13). Thereafter, many of the fibers are cleared.

Activated macrophages are stimulated to engulf and remove asbestos fibers. This process is not uniformly successful, however, and many fibers are retained (9, 10). The long fibers cannot be completely engulfed by the macrophage, as demonstrated in Figure 2.

Chrysotile fibers also split longitudinally, creating additional fibrils. These are cleared more efficiently than amphibole asbestos fibers, which may be retained indefinitely (12). The fibers induce apoptosis, a form of controlled cell death, in the macrophage and stimulate inflammation. This effect is reduced once the fiber is coated to create an asbestos body, but the great majority of fibers in the lung remain uncoated. For these reasons, asbestos has a prolonged residence in the lung, penetrates the interstitium of the distal lung, and shows extensive mobility both in the lung and around the body (9).

Asbestos fibers, in particular, stimulate macrophages to produce a variety of mediators. Oxygen radicals contribute to tissue injury. Granulocytes are recruited to sites of disease activity and they in turn release mediators that contribute to tissue fibrosis by stimulating fibroblast proliferation and chemotaxis and ultimately promoting collagen synthesis (11–15).

The inflammatory processes induced by asbestos include alveolitis, inflammation in the surrounding interstitium, and inflammation followed by fibrotic change in the respiratory bronchioles that extends into adjacent alveolar tissue (11, 14, 16). Studies of the lung tissue of asbestos-exposed workers, including non-smokers, have demonstrated a form of peribronchiolitis involving the walls of membranous and respiratory bronchioles, that shows characteristics of a more intense fibrotic response than the small airway lesions caused by nonspecific mineral dusts that the lesions otherwise resemble (17, 18).

Asbestos fibers and their derivatives, asbestos bodies, can be identified and quantified in lung tissue and bronchoalveolar lavage (BAL) specimens, as demonstrated in Figure 2 (19). Transbronchial lung biopsy is less reliable than BAL or open lung biopsy in recovering sufficient tissue to demonstrate elevated asbestos body or fiber counts when they do occur (20).

Asbestos fibers, unlike asbestos bodies, are rarely seen by light microscopy and must be analyzed by scanning/transmission electron microscopy (19, 21, 22). There is considerable variation among laboratories in procedures to quantify asbestos fibers in tissue (18, 23, 24), which has led to efforts to standardize procedures (19). Asbestos mineralogical types can be identified by energy-dispersive X-ray analysis, in which detection of magnesium and silicon is characteristic of most forms of asbestos and

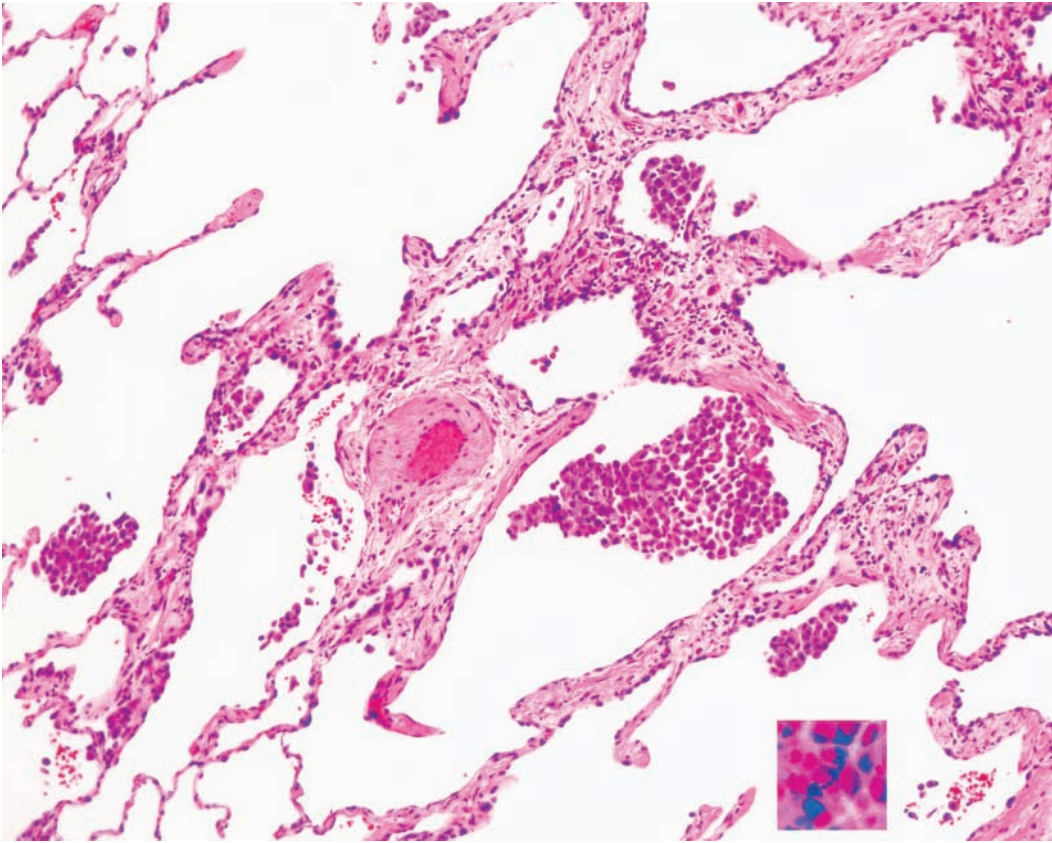


Figure 1. Low-power photomicrograph of hematoxylin and eosin (H&E)-stained sections from a patient with asbestosis, showing patchy asbestosis and a moderate number of macrophages within the alveoli. *Inset:* Close-up of macrophages in an iron-stained section showing an asbestos body.

the presence of a large iron peak signifies an amphibole (with the exception of tremolite) (25). Fiber analysis can be helpful in assessment of exposure and provides information about intensity, duration, and latency (e.g., uncoated fibers may reflect recent heavy exposure). However, because some fibers dissolve over

time, the absence of a high fiber count does not necessarily mean that there has been no exposure, especially when chrysotile is the predominant exposure (22). Mineralogic analysis of asbestos fibers is largely a research technique and is not widely available (26).

Asbestos bodies. Asbestos bodies are asbestos fibers that have

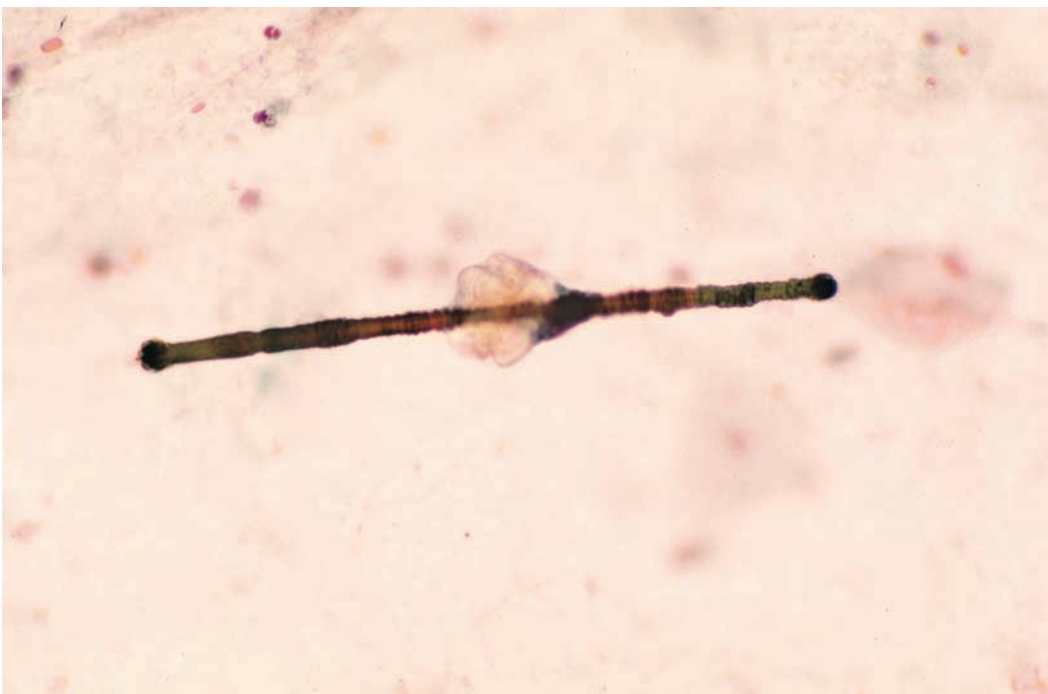


Figure 2. Asbestos body retrieved by bronchoalveolar lavage. Note its clear central core.

been coated with an iron-rich, proteinaceous concretion (Figures 1 and 2). Amphibole asbestos forms the majority of asbestos bodies and is more persistent in lung tissue than chrysotile (25). Asbestos bodies are larger than asbestos fibers and can be identified and quantified by light microscopy. An iron stain is helpful to identify fibrous bodies coated by iron (hence the general name "ferruginous bodies"). Ferruginous bodies generally form on fibers at least 10 μm in length, and more than 90% of all coated fibers have asbestos cores. Demonstration of an elevated body burden of asbestos confirms past exposure (19). Levels of at least one or two asbestos bodies per field of a tissue section on a slide under light microscopy are consistent with occupational exposure (19, 22, 24).

Transbronchial biopsy. Transbronchial lung biopsies are usually too small to analyze for asbestos bodies. Bronchoalveolar lavage recovers more material and therefore provides a better indicator of tissue burden. Some experienced clinicians have found that identification of six or more bodies in bleach-digested samples from at least two biopsies is characteristic of patients with occupational exposure (26). However, the absence of observable asbestos bodies is not reliable in excluding significant exposure in transbronchial biopsy tissue (20).

These indicators of fiber burden are sufficient but not necessary to identify occupational exposure and to diagnose asbestos-related disease. Beyond clinical research, the method has applications in litigation and exposure assessment for epidemiology.

Bronchoalveolar lavage. Asbestos bodies and fibers can be identified and quantified in BAL specimens, as in Figure 2 (22). There is considerable variation among laboratories in these tests (18, 19, 22, 23). The count of asbestos bodies in BAL fluid appears to correlate with the presence or degree of fibrosis in some studies but not others (24, 27, 28).

BAL in patients with asbestosis has demonstrated an alveolar macrophage alveolitis associated with a modest increase in neutrophils (12, 13). This neutrophilia correlates with the finding of crackles (rales) on physical examination and disturbances in oxygenation (12, 27) and is apt to be more pronounced in patients with advanced disease (13). Clinically apparent asbestosis occurs only after a significant latent period. However, studies using BAL, computed tomography (CT) scanning, and gallium-67 scanning have demonstrated that inflammatory events occur well before the onset of clinical disease. Thus, it is likely that the initial exposure induces inflammation and injury that persist through the latent or subclinical phase and later develop into the clinical disease, which is typically diagnosed by chest imaging (13).

CLINICAL EVALUATION AND INDICATORS

The clinical evaluation of nonmalignant asbestos-related disease should consider subjective symptoms as well as objective findings on physical examination, pulmonary function tests, and chest radiographic studies. In the large majority of patients, the diagnosis of nonmalignant asbestos-related lung disease is based on the clinical findings discussed below, in the context of an appropriate history of exposure to asbestos and a documented latency period sufficient to place an individual at risk.

Symptoms

The insidious onset of dyspnea is the most common respiratory symptom associated with asbestosis, typically beginning with dyspnea on exertion. A nonproductive cough is commonly present. The presence of wheeze or dyspnea (27), as reported on the ATS-DLD-78A respiratory questionnaire (5), is strongly associated with diminished ventilatory capacity in cross-sectional studies of asbestos-exposed workers, with an 11 to 17% reduction in ventilatory capacity (27, 29). A 2–8% reduction in ventilatory

capacity has been observed for cough, phlegm, and symptoms of chronic bronchitis among asbestos-exposed workers (29). Development or progression of respiratory symptoms has been associated with accelerated loss of ventilatory capacity in a longitudinal investigation of asbestos-exposed workers, with an excess 28-ml/year decline in FEV₁ associated with development of dyspnea, and 67-ml/year excess decline in FVC associated with newly developed wheezing, relative to asymptomatic individuals (30).

In a study of 64 patients, diffuse pleural thickening or fibrothorax was associated with dyspnea on exertion, usually mild, in 95%, chest pain in more than half, and restrictive defect in one-third. The chest pain was intermittent in most but constant in 9% (31). Rapidly progressive or severe chest pain should raise clinical suspicion of either malignancy or a nonmalignant pleuritis.

Subjective symptoms are not easily interpreted in the absence of objective findings but provide important ancillary information. The persistence or new onset of respiratory symptoms is correlated with accelerated loss of lung function in asbestos-exposed workers and therefore may predict future risk (30).

Occupational and Environmental History

It is essential to take a comprehensive occupational and environmental history when asbestos-related disease is suspected (32). The occupational history should emphasize occupational and environmental opportunities for exposure that occurred about 15 years and more before presentation.

The diagnosis of asbestosis is ideally based on an accurate exposure history, obtained whenever possible directly from the patient, that defines the duration, intensity, time of onset, and setting of exposure experienced by the patient. Patients may forget short periods of employment, during which intense exposure is possible, or employment early in their lives. In such cases the characteristic radiographic signs of asbestos exposure may be enough to document exposure.

The occupational title is not enough, as the names of many occupations and trades are uninformative, such as "millwright" or "fireman" (a misleading title that sometimes refers to furnace workers and stokers) or "mixer." Representative occupational exposures include, but are not limited to, manufacture of asbestos products, asbestos mining and milling, construction trades (including insulators, sheet metal workers, electricians, plumbers, pipefitters, and carpenters), power plant workers, boilermakers, and shipyard workers.

Asbestosis is commonly associated with prolonged exposure, usually over 10 to 20 years. However, short, intense exposures to asbestos, lasting from several months to 1 year or more, can be sufficient to cause asbestosis. For example, shipyard workers who applied or removed insulation in confined spaces have developed asbestosis after brief periods of heavy exposure. Insulation workers have had similarly intense exposures during their apprenticeship when they unloaded asbestos-containing sacks into troughs for mixing asbestos cement. Such occupational exposures are now rare but were common in the United States from the years after World War II until the 1970s. Adequate industrial hygiene controls were absent or not widely applied. Protective regulations were inadequate and only partially enforced during much of that period.

Workers whose own jobs may not require handling asbestos may still be "bystanders" who worked in close proximity to other users, especially in the construction trades, where workers have experienced exposure from insulation being installed around them. Among sheet metal workers, for example, the prevalence of asbestos-related changes on chest film was 31% (19% pleural only, 7% parenchymal only, and 6% both). Among those who had been in the trade for 40 or more years, 41.5% had radio-

graphic findings (33). These findings established that sheet metal workers, although not working directly with asbestos, had substantial exposure in the work environment.

Measures taken to protect workers, or lapses in these measures, may be important in documenting exposure. Although exposure levels are generally low in developed countries today, lapses occur and were more frequent in the past. Some patients who have immigrated may have worked in countries where occupational health regulations have been poorly enforced or where environmental exposure has occurred.

Environmental sources of exposure, for example, tailings of asbestos mines or prolonged exposure in buildings with exposed sources of asbestos contamination, may be important in some cases. Passive exposure, for example, of children in the home when asbestos is brought into the house on the clothes of a worker, may cause disease (34). Undisturbed and nonfriable asbestos insulation in buildings, including schools, does not present a hazard.

The prevalence of asbestosis among asbestos workers increases with the length of employment, as illustrated in an early report in which investigators analyzed chest films of 1,117 New York and New Jersey asbestos insulation workers. They found asbestosis in 10% of workers who had been employed for 10 to 19 years, 73% among those employed for 20 to 29 years, and in 92% of those employed for 40 or more years (35). A similar exposure–response relationship was found among asbestos cement workers (36).

Differences in solubility among the various types of asbestos may affect fiber retention, body burden, and the risk of nonmalignant disease. The clinician is rarely in a position to evaluate this aspect of exposure and there is no validated means to adjust the occupational history to take this factor into account. Solubility is primarily of concern with respect to projecting future risk, particularly of malignant disease, given a history of exposure. It is irrelevant to diagnosis when disease is already present and other indicators of exposure are demonstrable.

Physical Examination

Physical findings in asbestosis include basilar rales, often characterized by end-inspiratory crackles (rales) (36, 37); in some cases of advanced asbestosis, finger clubbing may be present. Physical findings of crackles, clubbing, or cyanosis are associated with increased risk for asbestos-related mortality (36). Although these physical signs are useful when present, their overall clinical utility is limited by low sensitivity. For example, in one study as many as 80% of individuals with radiographic asbestosis demonstrated crackles, a frequency that appears to be unusually high in the experience of other clinicians (27).

Conventional Imaging

The chest radiograph remains an extremely useful tool for the radiographic diagnosis of asbestosis and asbestos-related pleural disease, and is widely available internationally. The plain film has long been the basis for assessing asbestos-related disease of the lung and pleura. A standardized system for taking and classifying films for presence and profusion of opacities consistent with pneumoconiosis and for pleural changes was developed in the 1950s and is now known as the *International Classification of Radiographs of Pneumoconiosis* (or “ILO classification” after its sponsor, the International Labour Organization). The ILO classification has been revised (38). This system, which is the basis of the “B-reader” qualification for designating persons as competent in classifying pneumoconiosis films, was developed for grading the radiographic severity of pneumoconiosis in epidemiologic studies but has been applied to clinical settings to maintain consistency in classifying chest films. The ILO classification

requires conventional film-based posteroanterior (PA) chest films taken at prescribed specifications and classified with due regard for quality. Conventions for classifying digitized films and other advanced imaging systems have lagged behind the development of technology.

The initial radiographic presentation of asbestosis is typically that of bilateral small primarily irregular parenchymal opacities in the lower lobes bilaterally. Over time, the distribution and density or “profusion” of opacities may spread through the middle and upper lung zones. Although irregular opacities are most common from asbestos exposure, mixed irregular and rounded opacities are often present. The ILO classification profusion score correlates strongly with mortality risk (36), reduced diffusing capacity, and diminished ventilatory capacity (37, 39). A critical distinction is made between films that are suggestive but not presumptively diagnostic (0/1) and those that are presumptively diagnostic but not unequivocal (1/0). This dividing point is generally taken to separate films that are considered to be “positive” for asbestosis from those that are considered to be “negative.” However, profusion itself is continuous (36, 38).

Plain chest radiographs are limited with respect to sensitivity and specificity in cases of mild or early asbestosis. Among individuals with asbestosis confirmed by histopathologic findings, 15–20% had no radiographic evidence of parenchymal fibrosis in one study (40), similar to the proportion of other interstitial lung diseases that present with normal chest films (41).

Pleural plaques are frequently documented on plain chest radiographs, but CT is more sensitive for their detection. Only 50 to 80% of cases of documented pleural thickening demonstrated by autopsy, conventional CT, or high-resolution CT (HRCT) are detected by chest radiograph (42, 43). Plain chest radiographs are also limited by specificity in cases of mild pleural disease, which may be difficult to distinguish from extrapleural fat pads (39, 44). Oblique views can enhance both sensitivity and specificity of plain chest radiographs in clinical settings where HRCT is unavailable, but may also fail to distinguish plaques from fat pads (45). CT and HRCT are discussed in the next section.

Computed Tomography

A chest film clearly showing the characteristic signs of asbestosis in the presence of a compatible history of exposure is adequate for the diagnosis of the disease: further imaging procedures are not required. Conventional CT is superior to chest films in identifying parenchymal lesions, rounded atelectasis, and pleural plaques (46). However, conventional CT has been displaced by HRCT for the evaluation of asbestos-exposed subjects because the latter is more sensitive for detecting parenchymal fibrosis.

In subjects with low profusion categories of asbestosis, CT signs tend to be clustered as follows (47):

- Honeycombing and thickening of septa and interlobular fissures, suggesting interstitial fibrosis
- Diffuse pleural thickening, parenchymal bands, and rounded atelectasis, suggesting diffuse fibrosis involving the visceral pleura
- Pleural plaques

HRCT has an important role when experienced readers disagree about the presence or absence of abnormalities on a high-quality chest film, when chest radiographic findings are equivocal, when diminished pulmonary function is identified in association with otherwise normal plain chest radiographic findings, and when extensive overlying pleural abnormalities do not allow a clear interpretation of parenchymal markings. Because HRCT is more sensitive than other techniques for detecting parenchymal changes, it may reveal abnormalities with uncertain prognostic

significance. HRCT is more specific than plain chest radiographs, excluding conditions such as emphysema, vessel prominence, overlying pleural disease, and bronchiectasis, which may confound radiographic interpretation.

HRCT is much more sensitive in the detection of asbestosis than plain chest radiographs (46, 48), although even a normal HRCT cannot completely exclude asbestosis (49). Among asbestos-exposed individuals with unremarkable chest radiographic findings (ILO score 0/0 or 0/1), 34% were identified by HRCT as having findings suggestive of asbestosis. HRCT findings also correlated with decrements in pulmonary function tests in these cases, with a significantly diminished vital capacity and diffusing capacity (50).

HRCT can detect early pleural thickening (i.e., 1–2 mm in thickness) much more sensitively than plain chest radiographs. Pleural thickening is frequently discontinuous and interspersed with normal regions. It is usually bilateral but may be unilateral in a third of cases (48). HRCT also offers an advantage over plain chest radiographs in specificity, being able to distinguish pleural disease from extrapleural fat (51).

HRCT should be obtained at 2-cm intervals, to allow a more accurate assessment of pleural abnormalities, as well as other abnormal findings such as pulmonary masses (52). Prone views should always be obtained, as it is essential to distinguish between dependent atelectasis and parenchymal fibrosis in the posterior lung fields. HRCT findings in asbestosis are typically bilateral, and include evidence of fibrosis (e.g., intralobular interstitial thickening and interlobular septal thickening), subpleural “dotlike” opacities, subpleural lines, parenchymal bands, occasionally ground-glass opacity, and honeycombing in advanced disease (47, 52, 53). A proposal has been put forward for a classification system analogous to that of the ILO system for plain chest radiographs (54), but none has been widely adopted.

The extent of plaque formation does not correlate with cumulative asbestos exposure and thus cannot be used to estimate exposure (55).

Bronchoalveolar Lavage

Sputum analyses for asbestos bodies miss almost half of occupationally exposed individuals in whom asbestos bodies are found on BAL (56). Thus, on the rare occasions in which the diagnosis of asbestosis hinges on demonstration of asbestos bodies and fibers to document exposure, BAL should be performed if sputum analysis is negative (19). Subjects with long-term exposure have higher concentrations of fibers than those with more recent exposure, probably because of higher workplace exposures in the past (19).

Asbestos bodies (ABs) in BAL fluid correlate with occupational exposure and asbestosis (10, 19, 56, 57) and with asbestos bodies in the lung (57). Patients with asbestosis consistently have 2 to 5 orders of magnitude more ABs per milliliter than do pleural plaque subjects. Recovery of more than 1 AB/ml indicates a high probability of substantial occupational exposure to asbestos (19, 58). In one large series, patients with asbestosis had a log mean of 120 AB/ml, those with pleural plaques had 5 AB/ml, those exposed to asbestos who had a normal chest X-ray had 4 AB/ml, and those with malignant mesothelioma or lung cancer had 8 AB/ml. Of those with more than 100 AB/ml, 60% had asbestosis; others had pleural plaques, mesothelioma, or lung cancer, and only 6% were exposed but had no evidence of pathology (59).

BAL cells can also be digested with bleach and the residue analyzed by electron microscopy, with fibers expressed per 10^6 alveolar macrophages (58). In U.S. asbestos insulation workers, electron microscopy identified 1 chrysotile fiber in every 35 alveolar macrophages and 1 amosite fiber per 215 macrophages, with

no crocidolite detected. BAL performed on asbestos-exposed subjects has recovered 28×10^3 fibers compared with 1×10^3 in unexposed subjects (60). For every 100 fibers, there is typically 1 asbestos body (61). Clinically, the appearance of fibers or beaded fibers on a single centrifuged BAL sample mounted on a Diff-Quik slide represents an indicator of parenchymal asbestosis (28).

Amphibole fiber recovery on BAL correlates well with amphibole fiber burden in the lung, but the relationship does not hold for chrysotile because of translocation, clearance, and dissolution (57, 61–63).

Pulmonary Function Tests

Evaluation of subjects with suspected asbestos-related disease should include spirometry (with a hard copy of the flow–volume loop for the permanent medical record), all lung volumes, and the carbon monoxide diffusing capacity. Care should be taken to discriminate among effects due to asbestosis, chronic obstructive pulmonary disease, and restrictive changes due to obesity.

As with other interstitial lung diseases, the classic finding in asbestosis is a restrictive impairment. Mixed restrictive and obstructive impairment is frequently seen; isolated obstructive impairment is unusual. Restrictive impairment may also be observed with pleural disease (*see* section on pleural abnormalities below).

In addition to diminished lung volumes, the carbon monoxide diffusing capacity is commonly reduced due to diminished alveolar–capillary gas diffusion, as well as ventilation–perfusion mismatching. Although a low diffusing capacity for carbon monoxide is often reported as the most sensitive indicator of early asbestosis, it is also a relatively nonspecific finding.

Exercise testing is generally not required for diagnostic purposes, but may be useful in assessing aerobic work capacity in selected cases, or when the degree of dyspnea correlates poorly with objective pulmonary function measurements.

NONMALIGNANT DISEASE OUTCOMES

Asbestosis

Asbestosis is the interstitial pneumonitis and fibrosis caused by inhalation of asbestos fibers. After asbestos exposure, asbestosis becomes evident only after an appreciable latent period. The duration and intensity of exposure influence the prevalence of radiographically evident parenchymal pulmonary fibrosis. In work sites around the world that meet recommended control levels, high exposure to asbestos is now uncommon and clinical asbestosis is becoming a less severe disease that manifests itself after a longer latent interval.

Asbestosis specifically refers to interstitial fibrosis caused by the deposition of asbestos fibers in the lung (Figure 3). It does not refer to visceral pleural fibrosis, the subpleural extensions of fibrosis into the interlobular septae or lesions of the membranous bronchioles.

The College of American Pathologists has developed histologic criteria for asbestosis and a grading system to describe the severity and extent. The mildest (Grade I) form of asbestosis involves the alveolated walls of respiratory bronchioles and the alveolar ducts (Figures 4 and 5). More severe histologic grades involve greater proportions of the acinus (Grade II) until the whole acinar structure is involved (Grade III asbestosis) and some alveoli are completely obliterated (Figure 5). Alveolar collapse, with fibrosis and honeycomb remodeling resulting in new dilated spaces in the parenchyma, results in the most severe grade of asbestosis (Grade IV) (64, 65) (Figure 6). These patterns of acinar fibrosis together with the demonstration of asbestos bodies in standard histologic sections are diagnostic of asbestosis.

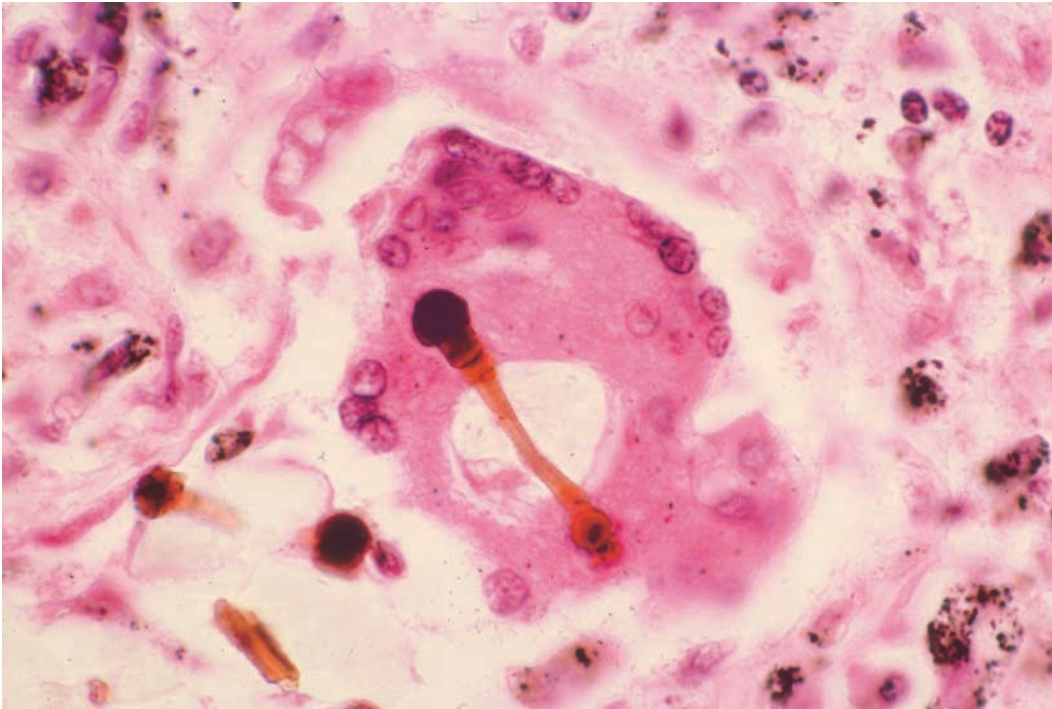


Figure 3. H&E-stained section demonstrating asbestos bodies within alveolus of person with asbestosis. At center is a single large asbestos body within a multinucleated giant cell.

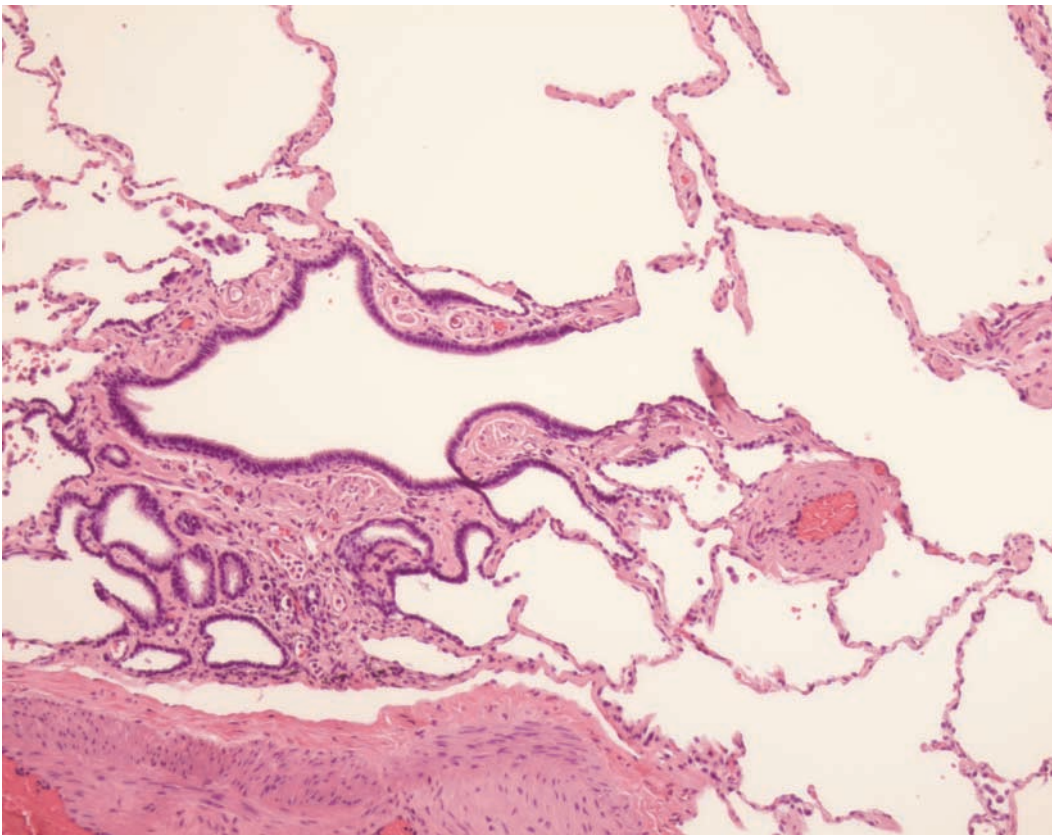


Figure 4. H&E-stained section showing junction of terminal (membranous) bronchiole with a respiratory bronchiole from a person with asbestosis who was an ex-smoker. The walls of the bronchioles are thickened by collagen and show mild smooth muscle hyperplasia. There is a mild chronic inflammatory cell infiltrate in the wall. These features are consistent with asbestos-related small airway disease.

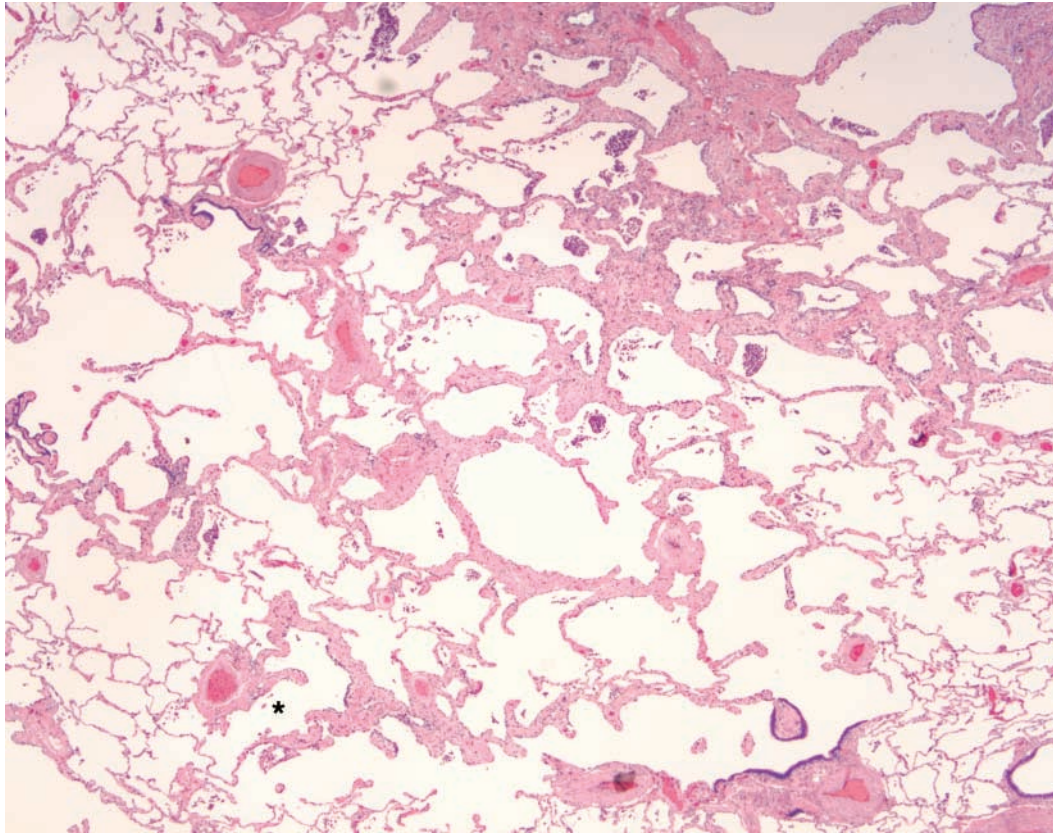


Figure 5. Photomicrograph showing predominantly Grade III asbestosis, partially defined by diffuse interstitial fibrosis extending from acinus to acinus. The respiratory bronchiole at *bottom left* (*) could be classified as a Grade I lesion (see Table 2).

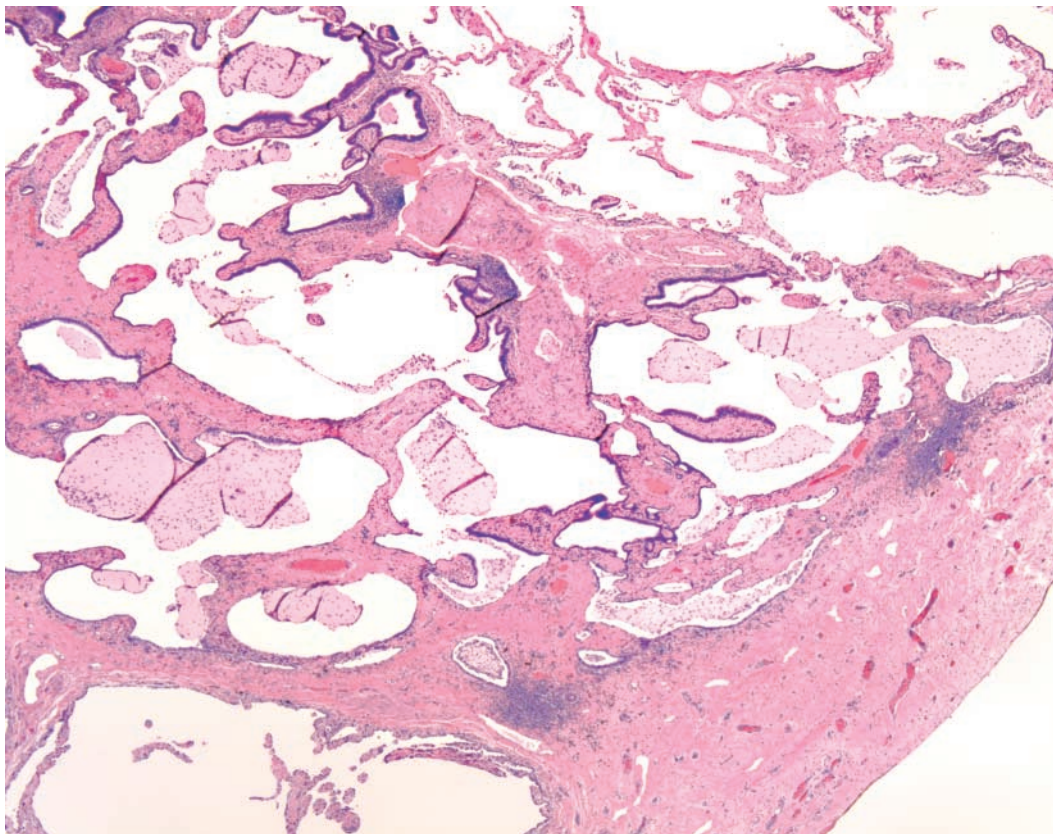


Figure 6. H&E-stained section of lung showing Grade IV asbestosis with honeycombing. The overlying pleura (*bottom right*) is also thickened.

TABLE 2. HISTOLOGIC GRADES OF ASBESTOSIS

Grade	Change
Grade of severity	
0	No fibrosis associated with bronchioles
1 or I	Early fibrosis involving walls of at least one respiratory bronchiole, with or without extension into septa of adjacent alveoli; fibrosis confined to alveolated walls of respiratory bronchioles and ducts and not present in more distant alveoli. Alveolitis and inflammation similar to that caused by cigarette smoking
2 or II	More severe fibrosis involving acinus: alveolar ducts and/or two or more layers of adjacent alveoli. Normal lung remains in a zone between adjacent bronchioles
3 or III	Fibrosis advanced and coalescent, involves entire acinus; all lung between at least two adjacent bronchioles is affected. Some alveoli are completely obliterated
4 or IV	Honeycomb remodeling and large (up to 1 cm) dilated spaces grossly visible in parenchyma
Grade of extent	
A or 1	Only occasional bronchioles are involved. Most appear normal
B or 2	"More than occasional" but less than half of bronchioles are involved
C or 3	More than half of bronchioles are involved

Developed in 1980 by a committee of the College of American Pathologists.

Iron stains may facilitate recognition of the asbestos bodies; however, the presence of asbestos bodies alone is not sufficient to establish the diagnosis of asbestosis. Asbestosis is associated with a variable degree (usually mild) of chronic inflammation and increased numbers of alveolar macrophages, including multinucleate giant cells. The grades of asbestosis correlate with counts and frequencies of asbestos fibers and bodies in the lung and estimates of cumulative workplace exposure (12, 66) (Table 2).

Only the more severe grades of asbestosis are detectable by gross examination. In its classic form, there is diffuse, bilateral, pale, firm fibrosis most severe in the peripheral zones of the lower lobes. Honeycomb cysts and areas of confluent fibrosis may be present (Figure 7). Milder forms of asbestosis and asbestos-associated small airway disease may not be apparent to gross inspection or to palpation, hence the importance of adequate sampling for histology. This should include peripheral and central areas of all lung lobes (depending on the specimen) as well as portions of visibly diseased lung. Adequate sampling of lung adjacent to resected tumors is particularly important and frequently overlooked or inadequately sampled by pathologists. It is strongly recommended that, when biopsy is performed, thoracic surgeons specifically request additional sampling of lung parenchyma in resected lung specimens from patients with known or suspected asbestos exposure (64, 65).

Asbestosis is more prevalent and more advanced for a given duration of exposure in cigarette smokers, presumably because of reduced clearance of asbestos fibers in the lung (67). Some studies suggest that smokers without dust exposure may show occasional irregular radiographic opacities on chest film, but if so the profusion is rarely as high as 1/0; smoking alone therefore does not result in a chest film with the characteristics of asbestosis (68). Both smokers and ex-smokers have a higher frequency of asbestos-related irregular opacities on their chest radiographs than do nonsmoking asbestos-exposed workers in all profusion categories (68–70). Smoking does not affect the presentation of asbestos-related pleural fibrosis.

Clinical diagnosis. Asbestosis is asbestos-induced pulmonary parenchymal fibrosis, with or without pleural thickening. To diagnose this disorder, one must establish the presence of pulmonary fibrosis and determine whether an exposure has occurred that is of sufficient duration, latency, and intensity to be causal.

Asbestosis becomes evident only after an appreciable latency period, often two decades under current conditions in the United States. In one study of former workers from an amosite asbestos insulation factory that had high levels of asbestos dust, employment for as little as 1 month resulted in a prevalence of 20% of parenchymal opacities 20 years after exposure ceased (70). The

duration and intensity of exposure probably influence the length of the latency period: relatively short-term, high-intensity exposures may be associated with a shorter latency than prolonged, lower intensity exposures.

Asbestosis is usually associated with dyspnea, bibasilar rales, and changes in pulmonary function: a restrictive pattern, mixed restrictive–obstructive pattern, and/or decreased diffusing capacity. The abnormal PA chest film and its interpretation remain the most important factors in establishing the presence of pulmonary fibrosis (Figure 8). Compensation systems may require that the chest radiographs be classified by the ILO system once it is established that the patient has been exposed to asbestos. A profusion of irregular opacities at the level of 1/0 is used as the boundary between normal and abnormal in the evaluation of the film, although the measure of profusion is continuous and there is no clear demarcation between 0/1 and 1/0 (Figure 9). When radiographic or lung function abnormalities are indeterminate, HRCT scanning is often useful in revealing characteristic parenchymal abnormalities as well as correlative pleural changes that are highly suggestive of asbestos exposure, particularly when they are bilateral. The specificity of the diagnosis of asbestosis increases with the number of consistent findings on chest film, the number of clinical features present (e.g., symptoms, signs, and pulmonary function changes), and the significance and strength of the history of exposure.

Although asbestosis is characteristically most advanced and appears earliest in the lower lung fields, there is a rare but well-characterized syndrome of massive bilateral upper lobe fibrosis, in the absence of tuberculosis or lung cancer (71–73).

The characteristic change in pulmonary function observed in asbestosis is a restrictive impairment, characterized by reduction in lung volumes (especially the FVC and total lung capacity), decreased diffusing capacity, and arterial hypoxemia (74, 75). Large airway function, as reflected by the FEV₁/FVC ratio, is generally well preserved. In one of the earliest studies conducted, about 50% of asbestos workers presented with FVC below 80% predicted. The frequency of abnormal vital capacity increased, and the mean vital capacity decreased by 18% over the subsequent 10 years (33, 75). The frequency and magnitude of the restrictive defect increased with ILO category (i.e., increased profusion of irregular opacities) and the presence of pleural changes.

Notwithstanding the predominantly parenchymal and restrictive pattern of the disease, airway obstruction can also be observed and can be seen alone in nonsmokers who have asbestosis. These patients usually have a restrictive pattern of lung function, but clinically they also feature an obstructive component charac-

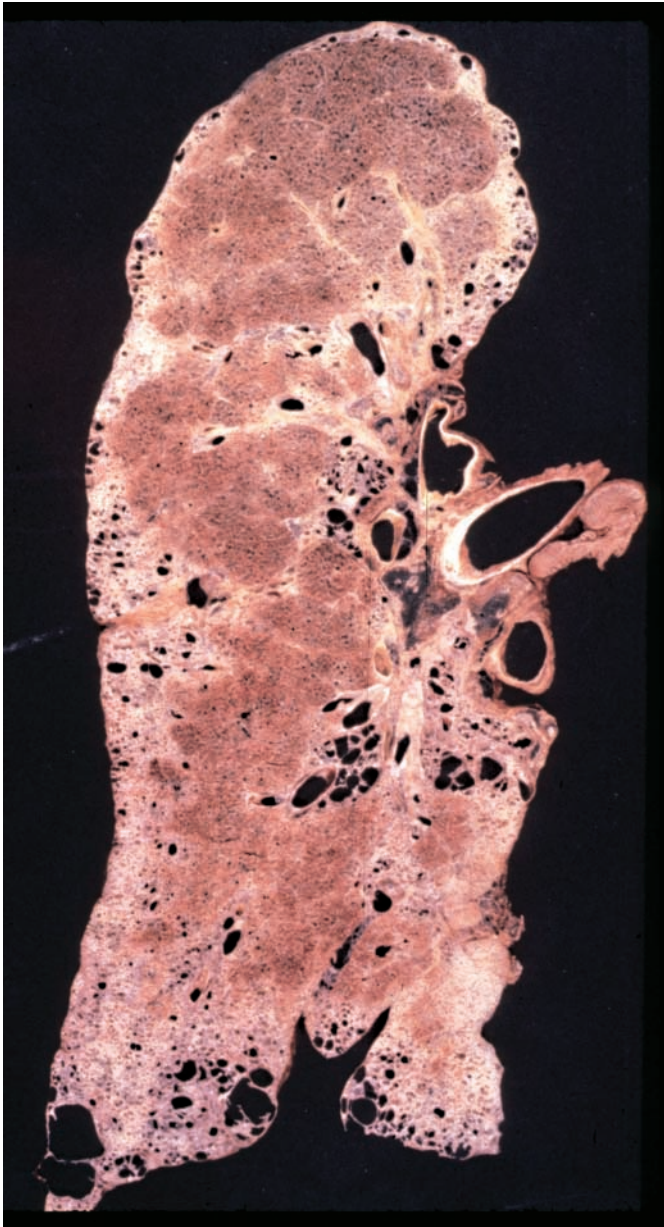


Figure 7. Whole lung section of freeze-dried lung from a person who died of asbestosis. Note the peripheral honeycombing, which is most severe in the lower zones.

terized physiologically by increased isoflow volume, and increased upstream resistance at low lung volumes (14, 16). These obstructive findings may be due to asbestos-induced small airway disease. Thus, mixed restrictive and obstructive abnormalities do not rule out asbestosis or necessarily imply that asbestos has not caused an obstructive functional impairment (76).

Asbestosis may remain static or progress; regression is rare (77). The factors that determine prognosis and evolution of the disease are poorly understood. Progression, after cessation of exposure or reduction to current permissible exposure levels, is considerably more common in persons who already have radiographic abnormalities and appears to be associated with level and duration of exposure and therefore cumulative exposure (78).

Differential diagnosis. Although not usually necessary for the

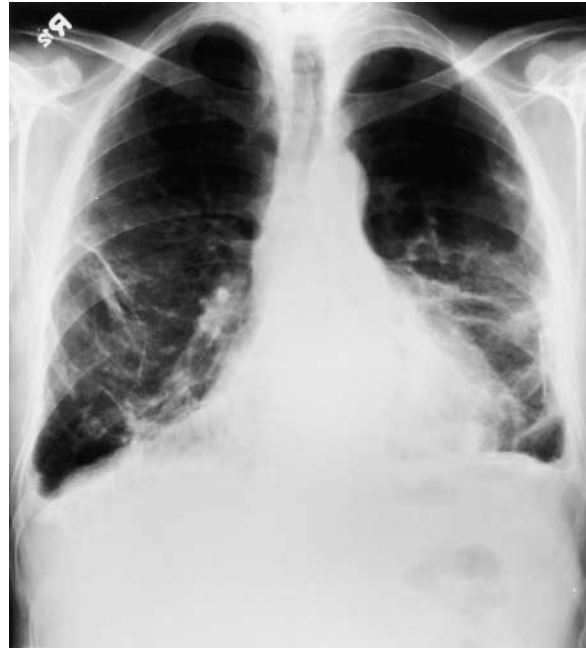

Figure 8. Advanced asbestosis (details of case not available). Note characteristic features: fibrotic bands superimposed on a background of widespread irregular opacities, shaggy heart border and septal thickening, extensive pleural changes, and blunted costophrenic angles.

diagnosis of asbestosis when a significant exposure history is obtained, lung biopsy may be warranted to exclude other, potentially treatable diseases. Biopsy material may be helpful in identifying the nature of a disease in an indeterminate case or one lacking an adequate exposure history.

The presence of asbestos bodies in tissue sections should be

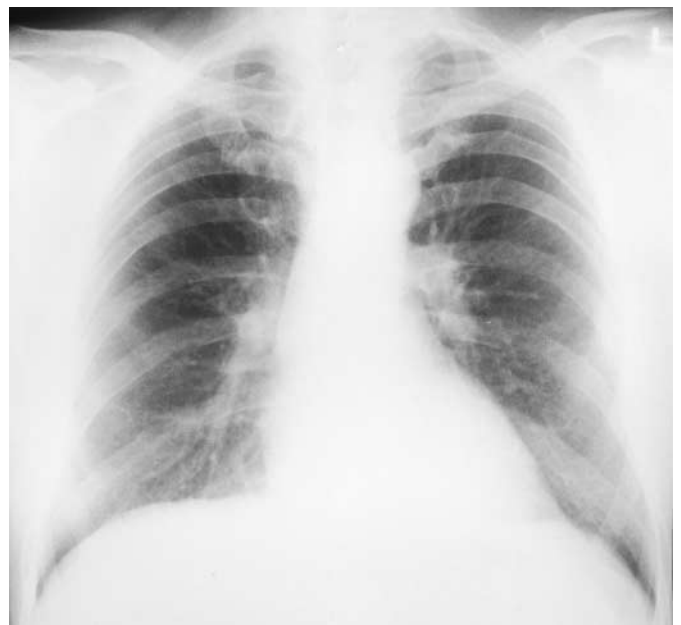


Figure 9. Early asbestosis, showing irregular opacities in lower lung fields that may be categorized as 0/1 or approaching 1/0 according to the ILO classification. Note pleural changes.

sufficient to differentiate asbestosis from other forms of interstitial fibrosis. The chance of finding one asbestos body from background exposure alone has been shown to be about 1 per 1,000 (79). Conversely, the presence of interstitial fibrosis in the absence of asbestos bodies is most likely not asbestosis, although rare cases of pulmonary fibrosis with large numbers of uncoated asbestos fibers have been described (80–82). Idiopathic pulmonary fibrosis (IPF in clinical terms or usual interstitial pneumonitis in terms of pathology) has an acinar pattern of fibrosis different from that of asbestosis and is not associated with asbestos bodies in tissue sections. On occasion, asbestosis is seen in conjunction with an unrelated interstitial lung disease (such as sarcoidosis) or in association with another pneumoconiosis, for example, silicosis. In the absence of fibrosis, asbestos bodies are an indication of exposure, not disease.

Asbestosis resembles a variety of other diffuse interstitial inflammatory and fibrotic processes in the lung and must be distinguished from other pneumoconioses, IPF, hypersensitivity pneumonitis, sarcoidosis, and other diseases of this class. The clinical features of asbestosis, although characteristic, are not individually unique or pathognomonic, but the characteristic signs of the disease are highly suggestive when they occur together. The presence of pleural plaques provides useful corollary evidence that the parenchymal process is asbestos related.

Diagnostic uncertainty is most likely in certain groups of patients. Patients may have a heavy cigarette-smoking history and concurrent emphysema (which also reduces the diffusing capacity). In such cases, one expects a history of asbestos exposure commensurate with the degree of disease. On occasion, a patient with another interstitial lung disease, such as IPF, will have a history of asbestos exposure. Rapid progression, with a visible, year-to-year increase in symptoms, progression of radiographic findings, and loss of pulmonary function in the absence of intense asbestos exposure, suggests the diagnosis of IPF rather than asbestosis.

Patients may be exposed at various times in their working life to more than one dust, such as silica and asbestos, or to mixed exposures, such as dusts in combination with fumes and vapors in welding (83). These patients may have combined disease or the effects of one dust or other exposure may dominate. For example, predominantly upper lobe rounded opacities, hilar node enlargement, and progressive massive fibrosis are not features of asbestosis and if present suggest other causes for the lung disease than asbestos, such as silicosis.

On occasion, isolated fibrotic lesions associated with asbestos resemble solitary pulmonary nodules. These are sometimes called “asbestomas” and usually occur against a background of irregular opacities; they rarely appear in isolation. They normally require biopsy because they are not distinguishable from lung malignancies otherwise (84).

Nonmalignant Pleural Abnormalities Associated with Asbestos

Pleural abnormalities associated with asbestos exposure are the result of collagen deposition resulting in subpleural thickening, which may subsequently calcify, and which in the visceral pleura may be associated with parenchymal fibrosis in adjacent subpleural alveoli (Figures 10 and 11). Pleural thickening, as a marker of asbestos exposure, has continued to be a prominent feature of exposure to asbestos while other outcomes, such as asbestosis, have become less frequent due to declining exposure levels. The major determinant of pleural thickening is duration from first exposure (70).

It is unclear whether the relative frequency of diffuse and circumscribed pleural thickening has changed. The *International Classification of Radiographs of Pneumoconioses* (38) provides

a basis for recording and classifying both types of pleural thickening, allowing correlation with indices of exposure and measurements of lung function. Manifestations of disease of the lung and of the pleura have become less evident and less characteristic on plain films as exposures have decreased. However, CT scan (including high-resolution images) detects pleural thickening not evident on the plain film, and sometimes fails to confirm apparent pleural thickening read on the plain film. Schemes to quantify extent of pleural thickening on CT scan have been published (55, 85). Rarely, interlobar pleural thickening may mimic lung nodules on CT scan (86).

Pleuritis: acute pleural effusion, chronic pleuritic pain. Asbestos may cause an acute pleural effusion, often lasting several months, that is exudative and often hemorrhagic, with variable numbers of erythrocytes, neutrophils, lymphocytes, mesothelial cells, and often eosinophils (87–89). It may occur early (within 10 years, unlike other asbestos-related diseases) or late after the onset of asbestos exposure (90). It may be superimposed on long-standing pleural plaques (91). Although it is usually asymptomatic, the acute pleural effusion due to asbestos may also be exuberant, with fever and severe pleuritic pain. It is sometimes detected only incidentally on a radiograph taken for another purpose (87, 88). The effusion may persist for months, present bilaterally, or recur on the same or the opposite side (87). A friction rub may be present (92, 93). The traces of pleural effusion may be observed years later as a blunted costophrenic angle or as diffuse pleural thickening. Acute pleuritis is thought to underlie many cases of diffuse pleural thickening. Of 20 insulators with a past history of definite pleural effusion, diffuse pleural thickening was detected on radiograph in 16 (90). Dose–response relationships or characteristic features of exposure associated with effusion have not been described.

Chronic severe pleuritic pain is rare in patients with asbestos-related pleural disease (92, 93). Vague discomfort appears to be more frequent. Studies examining the frequency of atypical chest pain in asbestos-exposed patients have not been performed. In the few cases described, it was present for many years, disabling, and often bilateral. Radiographic evidence of pleural disease ranged from plaques to extensive diffuse and circumscribed pleural thickening; several cases followed pleural effusions. The diagnosis of acute asbestos-related pleural effusion is by exclusion of other causes of acute pleuritis, and most often is not arrived at until the pleural space is fully explored and biopsied, generally by thoracoscopy. Differentiation from Dressler's syndrome is difficult in asbestos-exposed patients who have undergone recent cardiac surgery. Differentiation from mesothelioma or pleural extension of a pulmonary malignancy is critical, and may be difficult on clinical grounds (including positive gallium and positron emission scan). Pleural fluid cytology is useful for distinguishing benign from malignant effusions. It is not unusual for nonspecific effusions to precede mesothelioma by several years. If a malignancy has not manifested itself within 3 years, the effusion is generally considered benign.

The diagnosis of chronic pleuritis manifested by pleuritic pain is reached by excluding malignancies, because most other causes of acute pleuritis do not result in chronic pain. Malignancy is unlikely when pain persists for years with little or no clinical or radiographic change.

Plaques: circumscribed pleural thickening. Pleural plaques are indicators of exposure to asbestos. They are clearly the most common manifestation of the inhalation, retention, and biologic effect of asbestos. Their prevalence is most directly related to duration from first exposure; they are rare within less than 20 years. Pleural plaques consistent with asbestos exposure appear in chest films of 2.3% of U.S. males, a percentage that has been

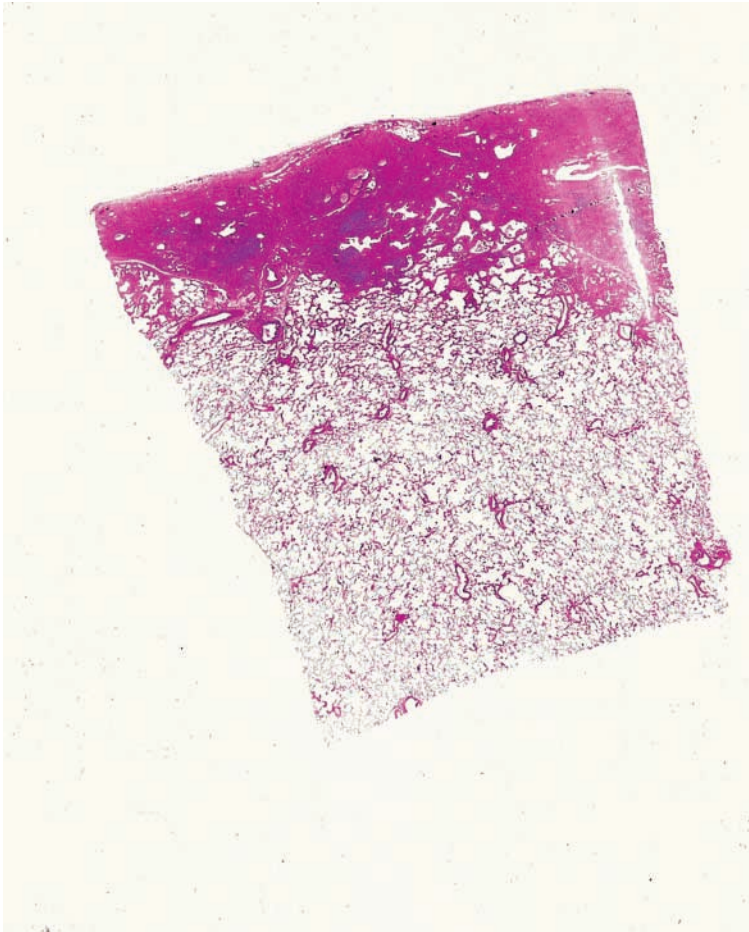


Figure 10. Photomicrograph of H&E-stained section of lung from a person with mild asbestosis. There is marked fibrosis of the pleura with some subpleural fibrosis. Higher power magnification of the same section showed that minimal disease was also present around the small respiratory bronchioles.

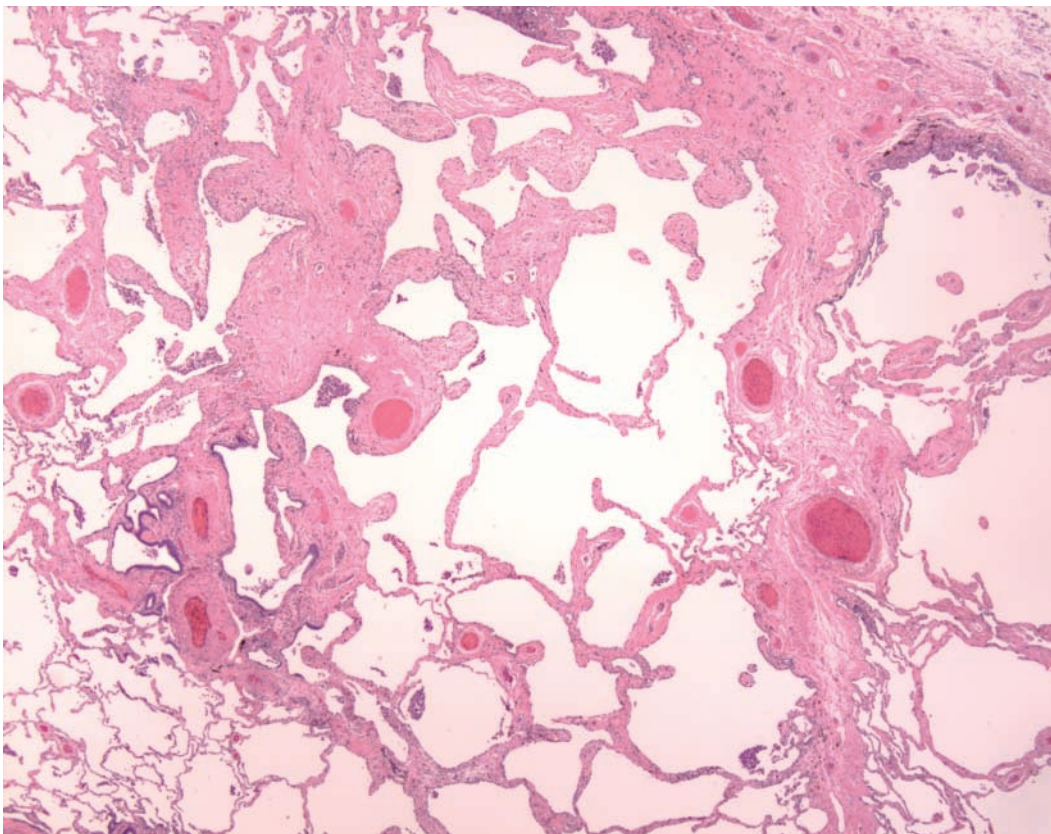


Figure 11. Photomicrograph of H&E-stained section of a person with Grade III asbestosis showing fibrosis in the lung parenchyma and overlying visceral pleura, with extension of the fibrosis into the interlobular septa.

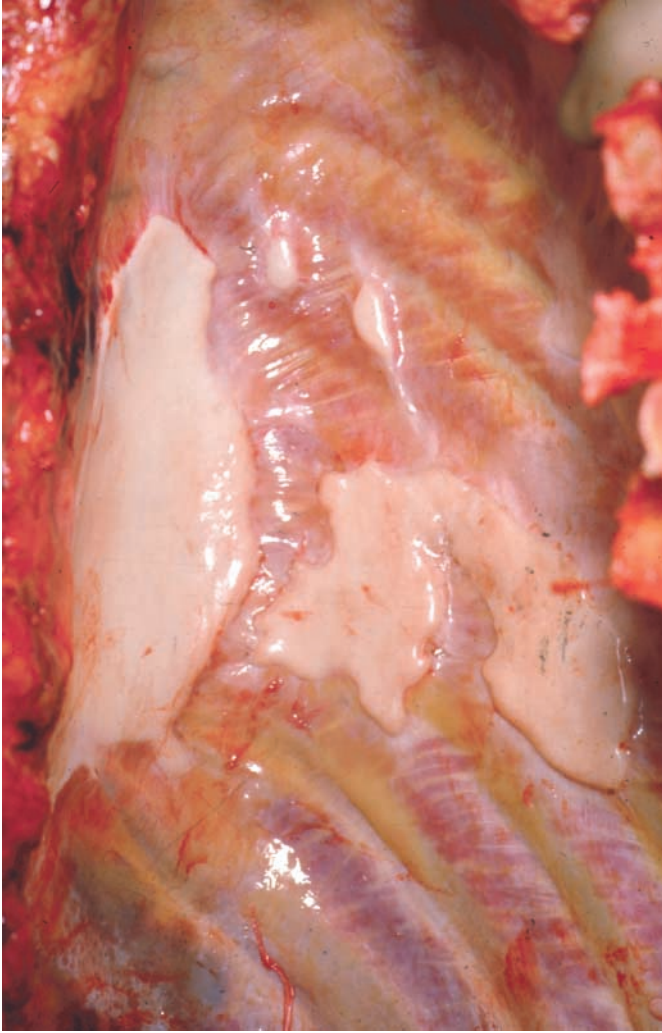


Figure 12. Gross appearance at autopsy of asbestos-associated pleural plaques overlying the lateral thoracic wall.

remarkably stable both for the general population in the early 1970s and veterans in the 1990s (94, 95).

Calcification is similarly related to duration. Smoking plays no role in the prevalence of pleural plaques (68). Pleural plaques are bilateral, but not symmetric, lesions of the parietal pleura. Characteristically, they are found following the ribs on the lower posterior thoracic wall (Figure 12) and over the central tendons of the diaphragm (Figure 13). They are raised, sharply circumscribed with a smooth or with a rounded knobby surface, and range in color from white to pale yellow. They generally spare the costophrenic angles and apices of the thoracic cavity. Microscopically, they consist of mature collagen fibers arranged in an open basket-weave pattern and are covered by flattened or cuboidal mesothelial cells. They are relatively avascular and acellular and show minimal inflammation. They are sharply demarcated from subpleural tissues and central calcification is common. Asbestos bodies are not seen in or adjacent to the lesions (64). Isolated plaques may be associated with tuberculosis, trauma, and hemothorax; however, multiple lesions having the classic appearances described above are almost invariably associated with asbestos exposure.

The conventional chest film is a sensitive and appropriate imaging method for plaques, although it may identify abnormalities that resemble plaques but are not. In the PA radiograph, they are best seen in profile on the midlateral chest walls and on the diaphragm or face on, and show serrated borders. HRCT is not a practical screening method for demonstrating plaques because of the separation between sections, the high radiation exposure, and the lack of access to the test in some locations. HRCT is useful to identify questionable abnormalities and to resolve questions about structures that resemble plaques.

Typical pleural plaques are easily identified on plain films by sharp, often foliate, borders (face on) and by a raised straight surface with clear, cut-off edges when seen face on (Figures 14–16) and as irregular margins (sometimes almost rectangular) when seen in profile on the chest wall or diaphragm. Apparent pleural thickening with gradually tapering or indistinct edges is often due to subpleural fat or superimposed soft tissue; fat pads below the parietal pleura typically occur in the midthoracic wall,

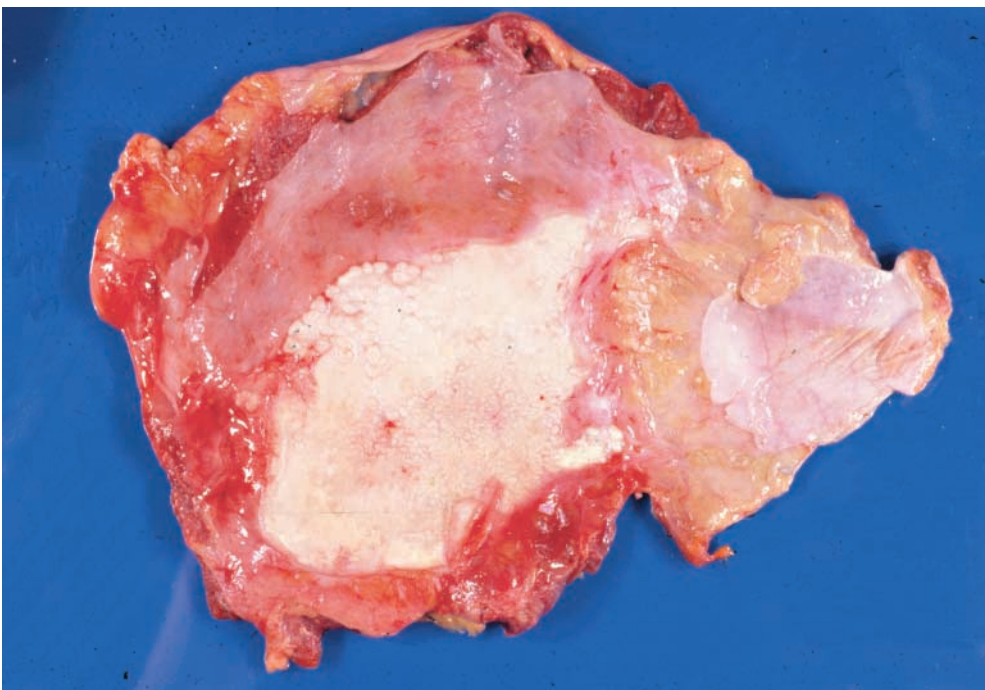


Figure 13. Gross appearance of large asbestos-related pleural plaque over the dome of the diaphragm.

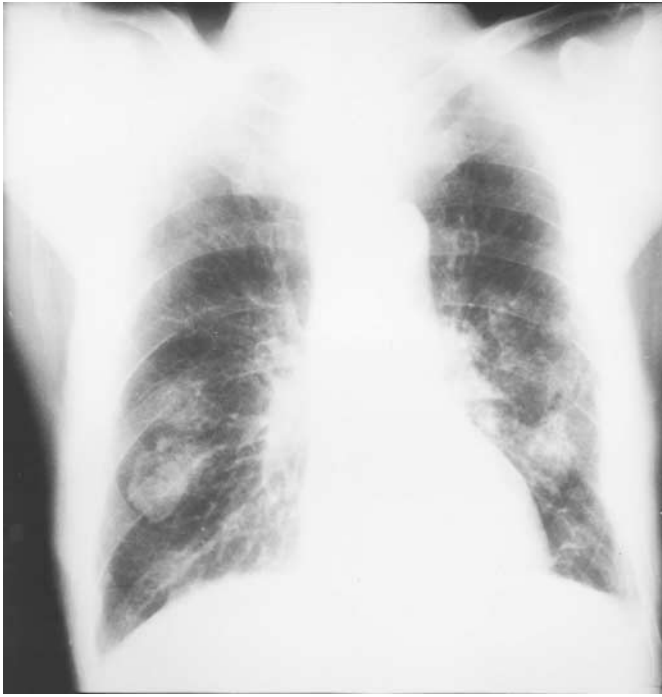

Figure 14. En face (face on) pleural plaques in a chest film with minimal parenchymal disease; worker was 54 years old at the time this chest film was taken (1982) and was exposed to asbestos in the 1960s as an insulation worker.

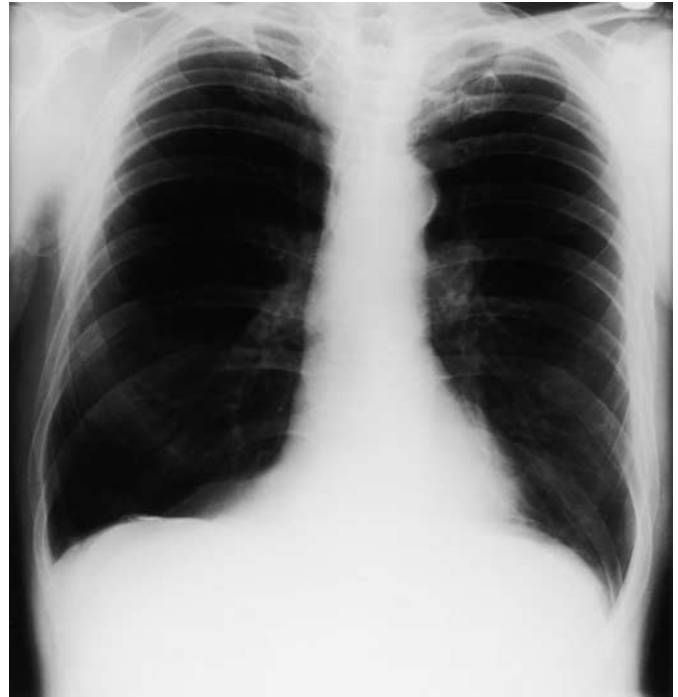

Figure 15. Pleural plaque, with linear calcification, seen on edge on the right hemidiaphragm in a 72-year-old sheet metal worker. No visible parenchymal disease.

between the fourth and eighth ribs, as do pleural plaques (51). Proper penetration is important on plain film; differentiation of fat from pleural plaques may still be difficult but is readily made by HRCT. Less typical plaques on the diaphragm may be difficult to detect and should be distinguished from atelectatic streaks, visceral folds, or diaphragmatic straightening caused by bullae. Calcification is helpful but may not be apparent in an underpenetrated film (Figure 14). Axial CT scans often fail to image diaphragmatic plaques (96).

The origin of pleural plaques is not clear (97, 98). The burden of asbestos fibers in lung tissue and of asbestos bodies in bronchoalveolar lavage fluid is greatly increased in patients with diffuse pleural thickening or asbestosis and moderately increased in patients with pleural plaques compared with unexposed subjects (99–101). The presence of pleural plaques is correlated with parenchymal disease, in particular fibrotic bands and both peribronchiolar and alveolar fibrosis. However, peribronchiolar fibrosis is absent in many cases with pleural plaques and present in many cases without them (102).

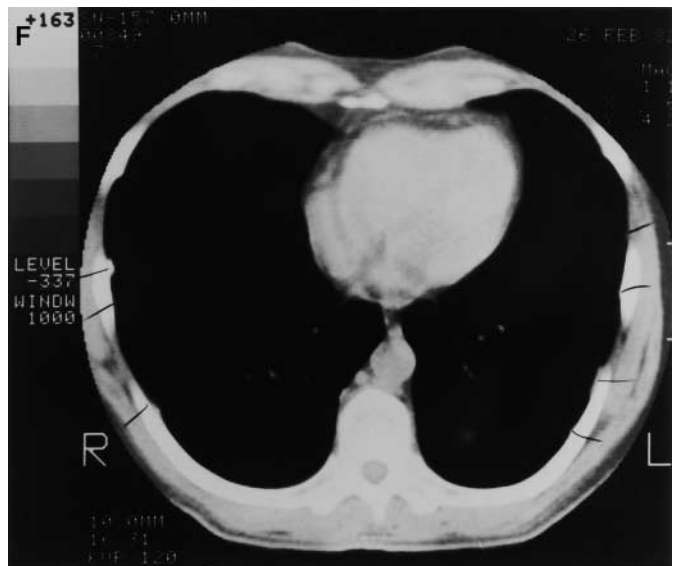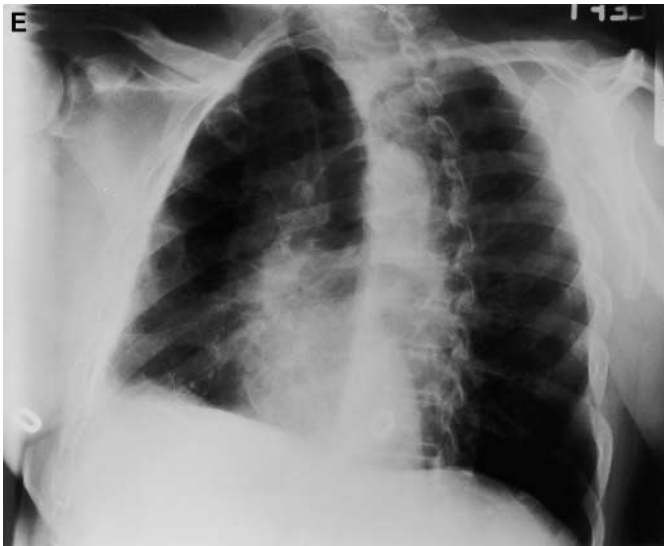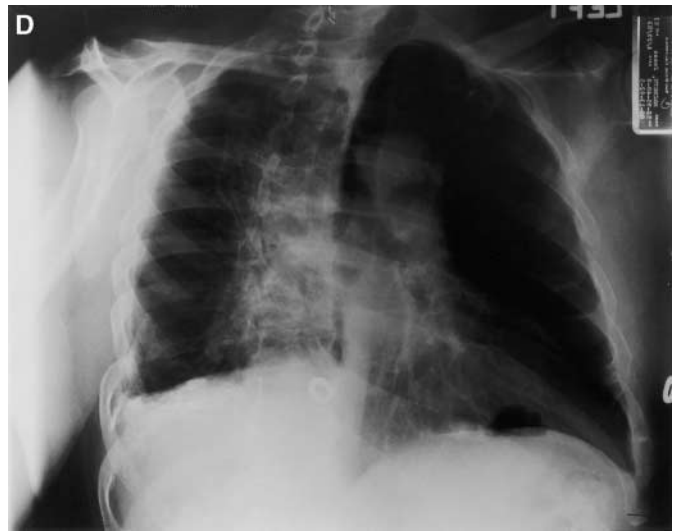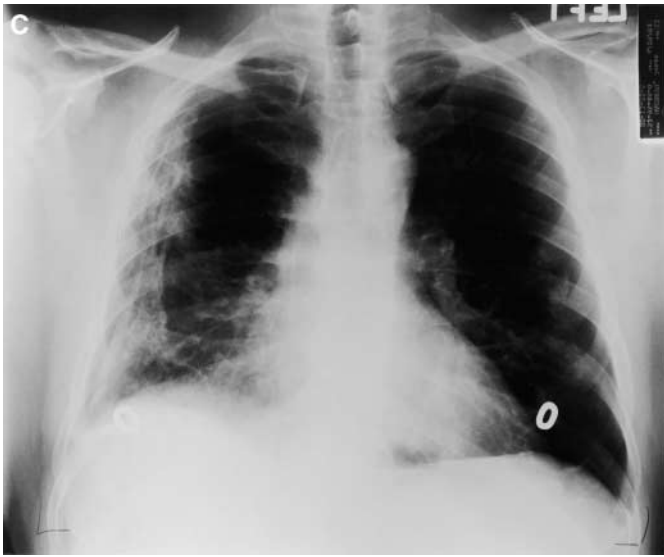
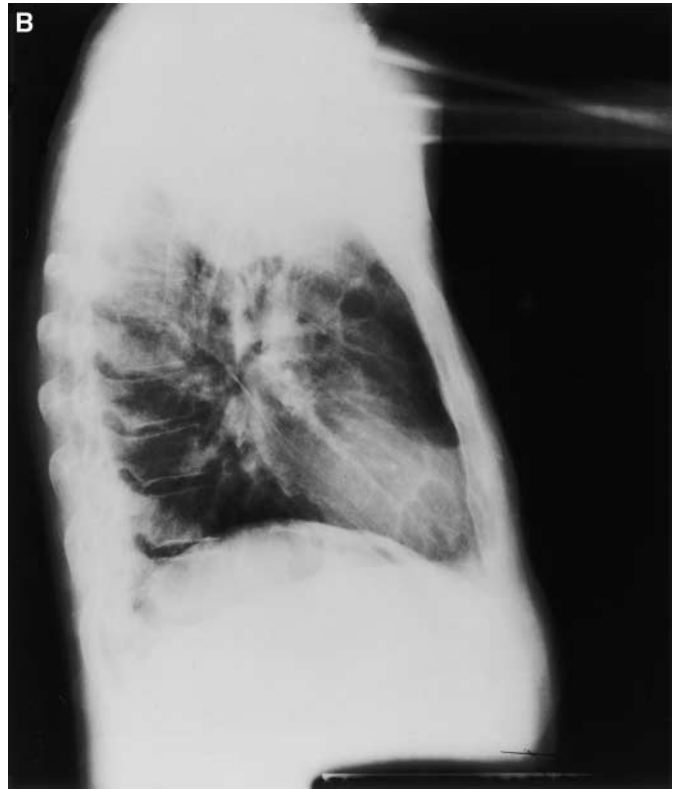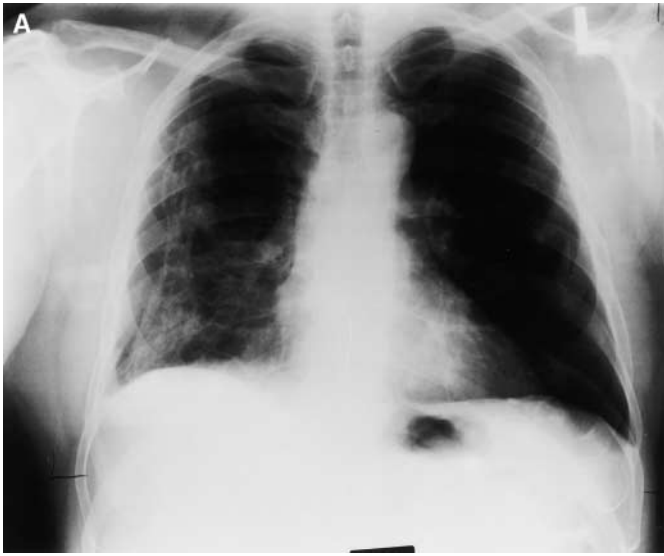
Slow progression of plaques is typical. Approximately 85% of heavily exposed workers showed pleural thickening (predominantly plaques) on plain film more than 40 years from first exposure (103), as did up to 17% of environmentally exposed populations (104). More than half the cases were bilateral.

The presence of plaques is associated with a greater risk of mesothelioma and of lung cancer compared with subjects with comparable histories of asbestos exposure who do not have plaques (105, 106). This is thought to be due to greater exposure or retained body burden, not malignant degeneration. Therefore, the presence of pleural plaques should be interpreted as a marker for elevated risk of malignancy, which may be higher than the occupational history alone might suggest.

Although pleural plaques have long been considered inconse-

quential markers of asbestos exposure, studies of large cohorts have shown a significant reduction in lung function attributable to the plaques, averaging about 5% of FVC, even when interstitial fibrosis (asbestosis) is absent radiographically (74, 76, 107). The presence of circumscribed plaques can be associated with restrictive impairment and diminished diffusing capacity on pulmonary function testing, even in the absence of radiographic evidence of interstitial fibrosis (108, 109). Taking into account the degree of interstitial fibrosis as measured by ILO profusion score (described below), smoking, and duration of asbestos exposure, significant decrements in vital capacity have been observed: a reduction of up 140 ml or more of FVC associated with circumscribed plaques (76). This has not been a consistent finding (110, 111) and longitudinal studies have not shown a more rapid decrement in pulmonary function in subjects with pleural plaques (112). Decrements, when they occur, are probably related to early subclinical fibrosis. Dyspnea on exertion was reported more often among subjects with circumscribed pleural thickening independent of parenchymal disease and appeared to be proportional to the extent (110). There is a significant but small association between the extent of circumscribed pleural plaques and FVC, which is not seen with diffuse pleural thickening (112, 113). Even so, most people with pleural plaques alone have well preserved lung function (55).

It is unclear whether this small effect on lung function is sufficient to contribute to dyspnea but there is evidence that it might. Half of subjects with pleural thickening but normal chest films and normal lung function showed excessive ventilation with exercise, which can contribute to dyspnea (114). Excessive ventilation on exercise could be the result of decreased chest wall and/or lung compliance caused by pleural thickening alone or to decreased lung compliance and ventilation-perfusion imbalance caused by parenchymal fibrosis that was not detected radiographically.



Plaques are indicators of increased risk for the future development of asbestosis (94). This may reflect greater exposure or retained body burden. An autopsy study has demonstrated more frequent peribronchiolar fibrosis when plaques are present (90). This finding, as well as derangements in gas exchange (114) and evidence from HRCT, indicate that subradiographic asbestosis may be present in some patients with only pleural plaques. The presence of plaques is therefore an indication to monitor the patient over time for interstitial fibrosis (115).

Diffuse pleural thickening. Diffuse thickening of the visceral pleura is not sharply demarcated and is often associated with fibrous strands (“crow’s feet”) extending into the parenchyma. In large surveys of asbestos-exposed workers, diffuse pleural thickening has ranged from 9 to 22% of those with pleural disease. Both circumscribed and diffuse pleural thickening may be present in the same hemithorax. Diffuse pleural thickening superimposed on circumscribed plaques has been observed, often after pleural effusion (91).

The frequency of diffuse pleural thickening increases with time from first exposure and is thought to be dose related (104). Diffuse pleural thickening has been observed after acute pleuritis (90). It may also be caused by extension of interstitial fibrosis to the visceral pleura, consistent with the pleural migration of asbestos fibers. The extent of diffuse pleural thickening seems to be more or less uniformly distributed, the different degrees being fairly equally often seen, however, in contradistinction to circumscribed pleural thickening, in which the lowest categories are more frequent (113). Lung burdens of asbestos in these cases are intermediate between asbestosis and pleural plaques (116–118).

This condition affects the visceral pleural surface and is quite different in appearance from the parietal pleural plaque. It consists of pale gray diffuse thickening that blends at the edges with the more normal pleura. It may be extensive and cover a whole lobe or whole lung and obliterate lobar fissures. It ranges in thickness from less than 1 mm up to 1 cm or more. Adhesions to the parietal pleura are common, particularly opposite to pleural plaques. The lesion may show a gradient with immature granulation tissue and fibrin at the surface, progressing to mature collagen adjacent to the lung. The fibrosis may extend for a few millimeters into the lung parenchyma and into the lobular septae. The latter features do not constitute asbestosis.

Diffuse pleural thickening may have a significantly greater impact on pulmonary function than circumscribed plaques. A reduction of 270 ml of FVC has been associated with diffuse pleural thickening (76, 119). Workers with diffuse pleural thickening have a significantly greater decrement in FVC (by a factor of two or more) than those with circumscribed pleural thickening (76, 113). This effect is unrelated to the radiographic extent of pleural thickening; a similar reduction in FVC was seen with little more than costophrenic angle blunting as with extensive involvement (113). Decrements associated with diffuse pleural thickening reflect pulmonary restriction as a result of adhesions of the parietal with the visceral pleura. Restrictive impairment is characteristic, with relative preservation of diffusing capacity (pattern of entrapped lung).

Diffuse pleural fibrosis extends continuously over a portion of the visceral pleura, often causing adhesions to the parietal pleura, involving the fissures and obliterating the costophrenic angle. The newly revised ILO classification (2003) recognizes pleural thickening as diffuse “only in the presence of and in continuity with, an obliterated costophrenic angle” (38). Localized subpleural parenchymal fibrosis is often present without diffuse interstitial fibrosis (117). Calcification of the pleura occurs with the passage of time, and may involve fissures. A rare variant of visceral pleural fibrosis is progressive apical thickening associated with fibrosis of the upper lobe (120, 121).

Pachypleuritis is extensive, often bilateral, pleural fibrosis with evidence of active inflammation histologically and by gallium uptake. Extension of fibrosis into the lung is often evident radiographically as irregular pleural and pericardial borders, fibrous streaks, or “crow’s feet” and bands. Ventilatory failure leading to CO₂ retention, cor pulmonale, and death has been described in four patients with bilateral involvement and little or no parenchymal fibrosis, and in one patient with unilateral pleural thickening. Decortication may be beneficial (122).

Rounded atelectasis. Rounded atelectasis (123, 124), also known as shrinking pleuritis, contracted pleurisy, pleuroma, Blelovsky’s syndrome (125), or folded lung, presents radiographically as a mass and may be mistaken for a tumor (Figure 17). The condition may result from pleuritis of any cause. The lesion is thought to develop from infolding of thickened visceral pleura with collapse of the intervening lung parenchyma. Clinical experience suggests that it is more likely to occur today as a result of asbestos exposure than other causes. The classic “comet sign” is pathognomonic and is often more readily seen on an HRCT than on plain films. Clues to its identity are a band connecting the mass to an area of thickened pleura and a slower evolution than that of a lung cancer, so that previous films will show a similar finding. Histologic examination shows folded and fibrotic visceral pleura with atelectasis and variable amounts of chronic inflammation in the adjacent lung parenchyma. The sudden appearance of rounded atelectasis may follow acute pleuritis with effusion. Rounded atelectasis may be multiple and bilateral (124, 126).

Rounded atelectasis is important for the diagnostic pathologist to recognize as it is frequently removed surgically as a suspected peripheral lung cancer. Asbestos bodies and/or evidence of asbestosis should be carefully sought.

Differential diagnosis, including rounded atelectasis and apical thickening. Acute pleuritis of any cause can result in diffuse pleural thickening that is indistinguishable from that associated with asbestos, although such causes are usually unilateral. The most likely causes, empyema, tuberculosis, and trauma, including surgery, are likely to be identified in the medical history. Empyema in childhood or an infected pleural effusion associated with pneumonia may not be.

The major differential diagnostic consideration with diffuse pleural thickening is mesothelioma, which is progressive and more likely to be symptomatic at the time of detection. On occasion, when fibrosis and mesothelial proliferation are exuberant, the distinction is difficult clinically, radiographically, and histologically. Apical thickening (120, 122) must also be distin-

Figure 16. Extensive evaluation in 1983 of a 65-year-old business executive who, in the 1950s, had worked in shipyards for approximately 2 years and was exposed to high levels of asbestos. This case is unusual because both early asbestosis and a huge pleural plaque are unilateral. (A) PA film shows asbestosis and an extensive pleural plaque extending over three-quarters of the length of the hemithorax. Right costophrenic angle is blunted but would not satisfy strict criteria for this according to the ILO classification. (B) Lateral film, showing extensive calcified plaques over diaphragm, also visible on *left* in PA film. (C) Because of concern for possible mass in right lower lung lobe, PA film was repeated with nipple markers: mass not seen in this view. (D) Left anterior oblique, showing absence of other plaques on chest wall. (E) Right anterior oblique, showing detail of plaque. (F) CT scan, showing plaque.

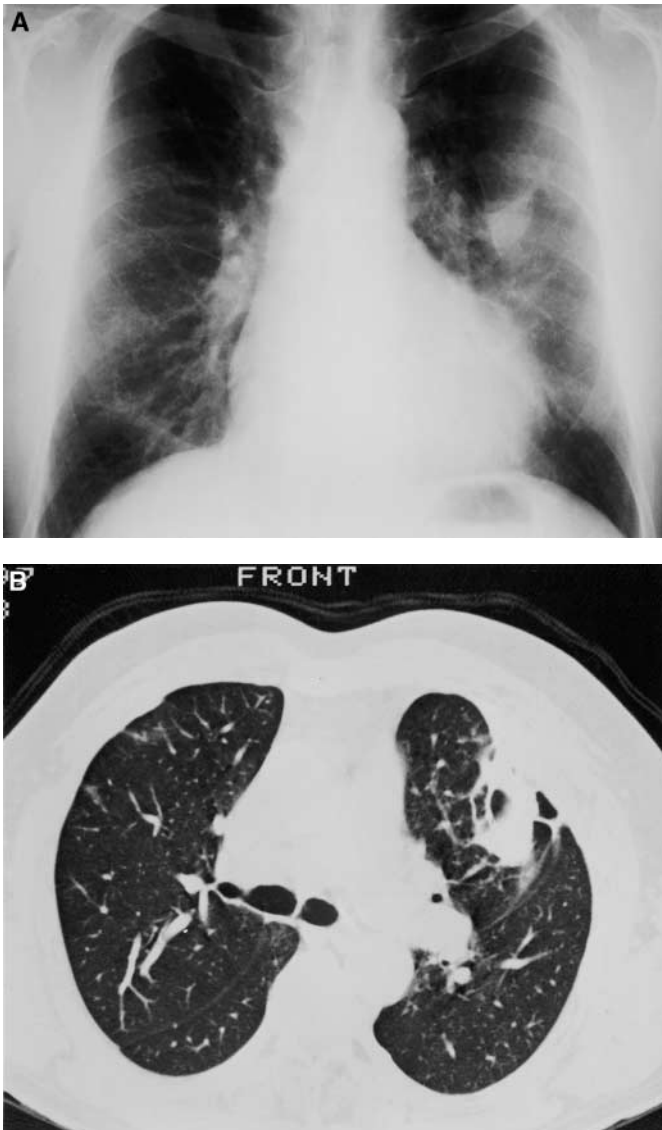


Figure 17. Rounded atelectasis in a 57-year-old sheet metal worker. (A) Presentation as a mass in the left chest. (B) CT scan showing pleural base and infolding of structures.

guished from mesothelioma and tuberculosis, which may be suggested by history and (previous) bacteriologic findings.

Chronic Airway Obstruction

Asbestos exposure has traditionally been considered to cause predominantly restrictive physiologic abnormalities. The role of asbestos as a cause of airway obstruction has been controversial. However, asbestos exposure has long been known to be associated with an obstructive physiological abnormality (127–129). This association might arise in one or more of several ways:

- Asbestos specifically causes obstructive abnormality.
- Asbestos causes obstructive abnormality nonspecifically (i.e., as do large burdens of most inorganic dusts) (83, 130).
- Work leading to extensive asbestos exposure is frequently associated with exposure to other agents affecting airways.
- Confounding by tobacco smoking may lead to an association.
- Anatomic and physiologic airway abnormalities develop

as part of the pathophysiologic process of asbestosis and are not an independent entity.

Asbestos-related chronic airway obstruction may result in reduction in the FEV₁/FVC ratio associated with reduced FEV₁ (29, 76, 113, 127). Epidemiologic studies have demonstrated a significant association between asbestos exposure or asbestosis category as defined radiographically and reduction in FEV₁, FEV₁/FVC ratio, and midexpiratory flow rates (111, 130–133). The relationship between surrogate measures of exposure and the FEV₁ and FEV₁/FVC ratio also occurs in subjects who do not have radiographic evidence of asbestosis (defined as an ILO score exceeding 1/0) (130, 133, 134). A small effect has been observed in lifelong nonsmokers (14, 113, 135, 136). This effect begins in small airways, consistent with the known pathology of bronchiolitis in early asbestosis (136, 137). Radiographically, airflow abnormalities may also be associated with emphysema (138).

Histologically, inflammation and airway fibrosis characterize asbestos-related small airway disease. A major site of asbestos deposition is in the walls of membranous and respiratory bronchioles. In the walls of membranous bronchioles this leads to fibrosis and smooth muscle hyperplasia that are similar, but more severe, than that produced by cigarette smoking (128, 139) (Figures 4, 5, and 18). The respiratory bronchioles show fibrosis, which extends into the alveolated portions of the walls and alveolar ducts (Figure 19). In this regard, it differs from the lesion of cigarette smoking, which primarily involves the nonalveolated portions of the first generation of respiratory bronchioles (140). Asbestos bodies are not present in the walls of the membranous bronchioles, although inflammatory changes are present, but are commonly seen in the walls of the respiratory bronchioles and/or adjacent alveoli. Some authorities consider it appropriate to describe these lesions as true asbestosis because the walls of respiratory bronchioles are largely alveolated and therefore within the gas exchange region of the lung (64). Others consider the small airway lesions as distinct from asbestosis and refer to the lesions of both membranous and respiratory bronchioles as asbestos-induced small airway disease (12). These small airway lesions are the likely anatomic basis for airflow limitation in asbestos-exposed individuals.

In general, the magnitude of the asbestos effect on airway function is relatively small. This effect, by itself, is unlikely to result in functional impairment or the usual symptoms and signs of chronic obstructive pulmonary disease. However, if superimposed on another disease process, the additional loss of function due to the asbestos effect might contribute significantly to increased functional impairment, especially in persons with low lung function.

Asbestos exposure independently contributes to accelerated decline in airflow over time, whether or not exposure ceases (77, 129, 133, 134, 141). Dyspnea, cigarette smoking, diffuse pleural thickening, honeycombing observed on HRCT scan, and indicators of active inflammation have been associated with worsening obstruction (142). Effects on measures of early small airway dysfunction (e.g., midexpiratory flow rates) in themselves are unlikely to produce clinically relevant impairment, but may indicate an increased probability that disease will develop later (128, 129, 134, 143). Development or persistence of respiratory symptoms among asbestos-exposed workers is associated with accelerated loss of lung function, both FVC and FEV₁ (30). In patients with severe obstructive airway disease from another cause, the additional contribution of asbestos-related airflow obstruction might be functionally significant at low levels of lung function. Short duration and low cumulative exposure are less likely to produce significant obstructive abnormality (112, 134).

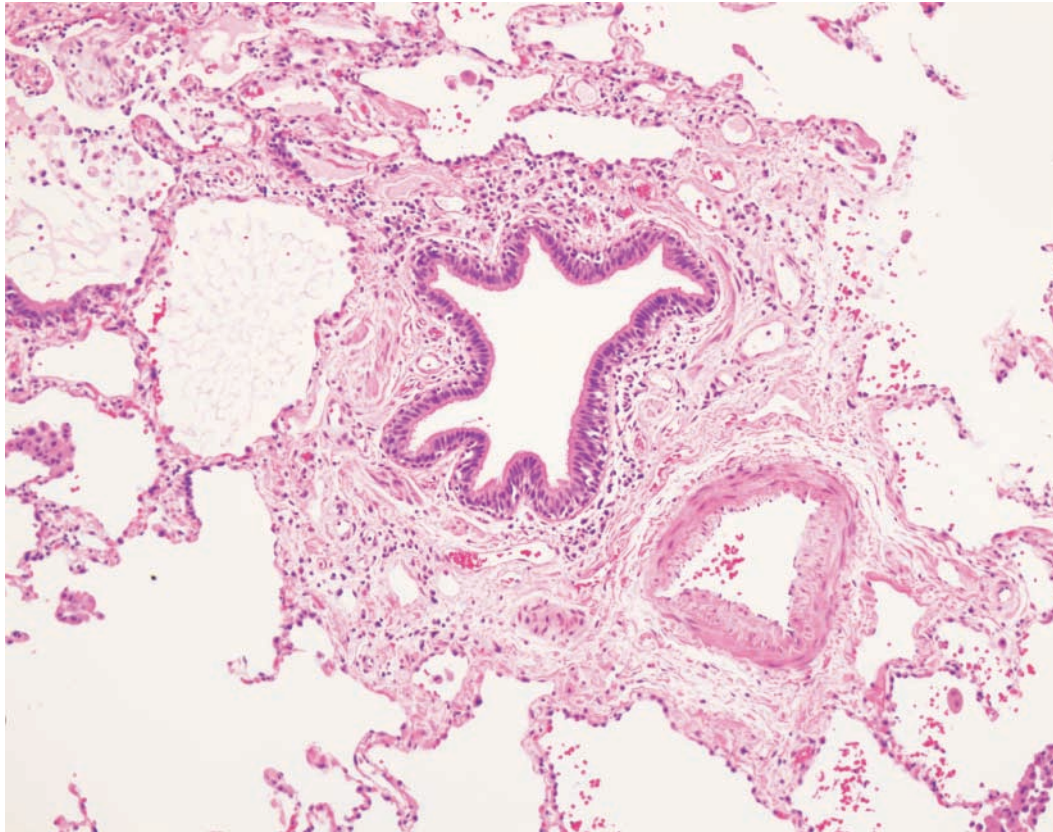


Figure 18. Photomicrograph of asbestos-related small airway disease, showing thickened membranous bronchiole. There is also fibrosis around the airway, and a mild chronic inflammatory cell infiltrate in its wall.

Assessment of functional impairment of clinical significance (3) should generally be based on the restrictive findings associated with asbestosis, as these are more likely to be disabling. However, the addition of obstructive disease adds to the level of functional impairment (144). Treating restriction and obstruction separately may underestimate their combined effect on impairment. The normal indicator for restrictive impairment, total lung capacity, has proven to be insensitive to total impairment in subjects with both asbestosis and chronic obstructive lung disease. In such cases, diffusing capacity and alveolar–arterial oxygen difference may be more revealing (144). Some of the restrictive component may be contributed by air trapping rather than fibrosis (145).

Chronic obstructive airway disease that is not due to asbestos (e.g., secondary to smoking) may complicate the recognition of asbestosis. For example, total lung capacity may be normal when both disorders are present, due to a restrictive process offsetting air trapping (143). Whereas the FEV₁/FVC ratio may be reduced in asbestos-exposed persons with no or a low profusion of small, irregular opacities, this ratio may also be normal in more advanced asbestosis (i.e., with higher profusion and diminished FVC) because of a reduction in FVC (75).

Effects on airflow begin before the development of asbestosis (129). In individuals who develop asbestosis, physiologic findings associated with airflow obstruction (e.g., reduction in the FEV₁/FVC ratio) become less prominent as asbestosis progresses; this may reflect increased pulmonary recoil.

The dose and time course of asbestos-associated airway abnormalities have received limited attention. Many available stud-

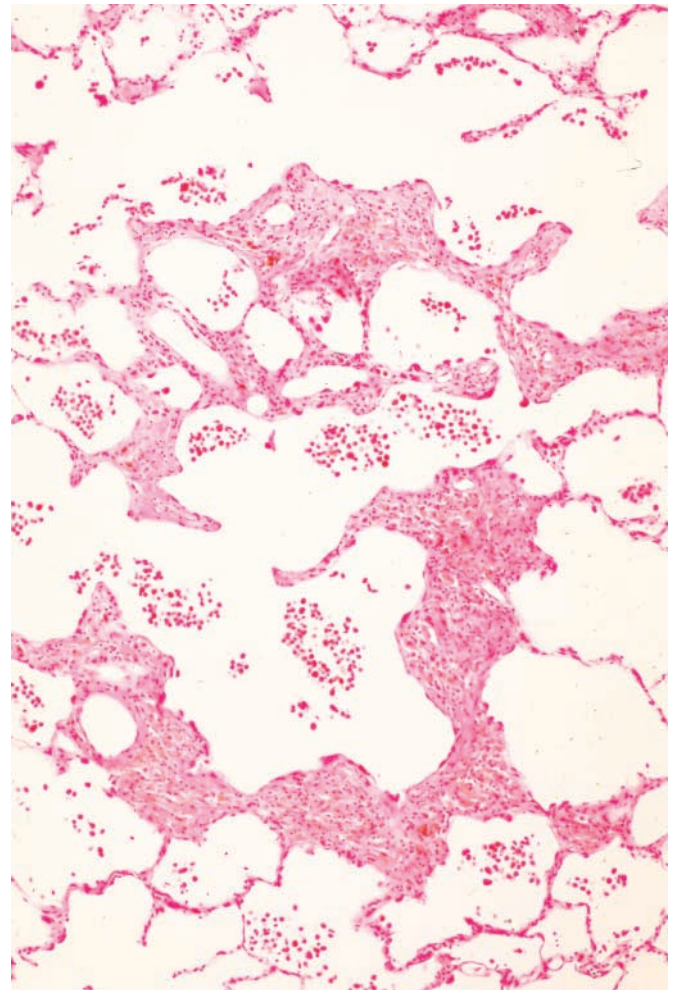


Figure 19. Photomicrograph of asbestos-related small airway disease, in this case a respiratory bronchiole, with extension of the fibrosis into the adjacent parenchyma (Grade II asbestosis; see Table 2).

TABLE 3. RECOMMENDATIONS FOR MANAGEMENT AFTER DIAGNOSIS OF ASBESTOSIS

-
1. Patient notification
 - 1.1. Inform patient of work-related illness
 - 1.2. Report to appropriate authority as occupational disease, as required by law
 - 1.3. Inform patient that there are options for compensation
 2. Impairment assessment
 - 2.1. Conduct an assessment of functional impairment
 - 2.2. Rate impairment in accordance with ATS criteria,* which are incorporated into the AMA Guides[†]
 3. Tertiary prevention
 - 3.1. Smoking cessation (primary prevention for smoking-related disorders)
 - 3.2. Withdrawal from further excessive exposure[‡]
 - 3.3. Immunization (pneumococcal pneumonia, influenza)
 - 3.4. Management of concurrent respiratory and other diseases
 4. Monitoring
 - 4.1. Chest film and pulmonary function testing[§] should be conducted every 3 to 5 years
 - 4.2. Active monitoring (periodic screening) for colon cancer
 - 4.3. Observation and elevated index of suspicion but not screening for lung cancer, mesothelioma, gastrointestinal cancers (other than colon)
 5. Development of a patient-specific management plan for symptomatic disease
-

Definition of abbreviations: AMA = American Medical Association; ATS = American Thoracic Society.

* See Reference 3.

† See Reference 157.

‡ See text.

§ See References 4 and 5.

ies reflect relatively high historical levels of exposure. Among nonsmoking Chinese asbestos workers, association of cumulative exposure with functional effects was seen only among those with long-term exposure (133).

Tobacco smoking is the predominant cause of chronic airway obstruction in asbestos-exposed workers who smoke, although occupational exposures can be significant. The association between airway obstruction and exposure to asbestos has been well demonstrated in nonsmokers, and in some studies the association between exposure and airway obstruction is seen only among nonsmokers (131); among smoking asbestos-exposed workers, smoking accounts for most of the small airway abnormality (111, 127, 135, 141, 142). In addition to smoking, other occupational exposures might contribute to chronic obstructive airway disease; effects of asbestos in producing airflow obstruction are likely to be additive to these. There may be an interaction between smoking and asbestos in the development of airway obstruction, as has been demonstrated in animal models (146), but this has not yet been demonstrated for human subjects.

IMPLICATIONS OF DIAGNOSIS FOR PATIENT MANAGEMENT

A history of significant asbestos exposure obligates the responsible physician to provide a management plan for the patient that takes into consideration current disease and impairment as well as future risk (147). A recommended management plan is summarized in Table 3.

Workers referred for evaluation of asbestos-related disease today differ from those referred in past years. Exposure to asbestos among these workers is likely to be more remote in time and to have been less intense. Exposed workers may live longer and progress later to more advanced stages of disease. They are more likely to survive to develop additional outcomes associated with asbestos, such as malignancy, and to present more complicated management challenges (148).

Actions Required before Disease Is Apparent

A recent or short-term history of exposure to asbestos, particularly in the absence of detail on duration and intensity, requires the clinician at a minimum to educate the patient with respect

to latency, the exposure–response relationship characteristic of asbestos-related diseases, and the future risk of malignant disease. Reassurance should be offered where appropriate and the risk placed into the context of the exposure history. This is often an excellent opportunity at the same time to review the patient's history, work hygiene practices, behavior and attitudes toward cigarette smoking, as well as exposure to other occupational and environmental carcinogens (149).

For all patients presenting with a history of significant or possibly significant exposure, at a minimum a baseline, high-quality chest film should be obtained, together with spirometry and a single-breath diffusing capacity that conform to American Thoracic Society guidelines. Complete pulmonary function testing should be obtained if clinically indicated. Workers who have had exposure to asbestos have also often worked in other dusty occupations. They and their families may have lived in communities where they experienced environmental exposures.

The sensitivity of the plain chest film for identifying asbestosis at a profusion level of 1/0 (in the ILO classification system) has been estimated at or slightly below 90%. The corresponding specificity has been estimated at 93%. Applied to populations with varying prevalence of disease, the positive predictive value of the minimally abnormal chest film alone in making the diagnosis of asbestosis may fall below 30% when exposure to asbestos has been infrequent and exceed 50% when it has been prevalent. This suggests that screening programs based on the chest film alone may vary considerably in their yield of true cases depending on the characteristics of the population being screened. In the general population and for occupational groups with low levels of exposure they may be unreliable in identifying asbestosis. The application of multiple criteria, as outlined in this statement, is a preferable approach (150). However, combinations of tests for a specific criterion, such as a hypothetical requirement that multiple tests for pulmonary function be abnormal, would reduce the sensitivity without enhancing specificity for asbestos-related disease; in general, the most sensitive test for a particular criterion is preferable (2).

Persons identified as having asbestos-related disease or a significant exposure history should be informed of the risk of progression of disease, the risk of malignancy, and especially

the interaction between smoking and asbestos exposure in enhancing the risk of lung cancer. Such persons who smoke may be more motivated to consider cessation when the connection between asbestos and the risk of respiratory impairment and of malignancy is brought up at this time (151). The risk conferred by other occupational and environmental carcinogens should also be emphasized at this time.

The question of monitoring for asbestos-related disease is complicated by requirements for occupational surveillance, especially for those with minimal exposure. The Occupational Safety and Health Administration asbestos standard requires employers to monitor their asbestos-exposed workers during employment but makes no provision beyond the period of employment, despite the latency, and private insurance may or may not allow the expense thereafter (8).

Persons with a history of exposure to asbestos but no manifest disease, and for whom the time since initial exposure is 10 years or more, may reasonably be monitored with chest films and pulmonary function studies every 3 to 5 years to identify the onset of asbestos-related disease.

Persons with a history of exposure to asbestos are also at risk for asbestos-related malignancies. Periodic health surveillance for lung cancer or mesothelioma is not recommended. Screening for lung cancer using periodic (annual) chest films, low-dose computed tomography, or sputum cytology has not been shown to be effective in preventing mortality or improving quality of life in populations of smokers without known adverse occupational exposures (152, 153). New technologies (e.g., low-dose spiral CT scanning) are being evaluated for use in high-risk groups (153). The risk of extrathoracic malignancies may also be increased in asbestos-exposed workers. Studies suggest that there may be an elevation in the risk of colon cancer (149, 150), although this remains controversial (154). Because colon cancer is often treatable and screening for colorectal cancer is recommended by the American Cancer Society for persons more than 50 years of age (155), it is reasonable on the basis of current evidence to screen for this condition. The risk of cancer of the larynx (156) and possibly gastrointestinal cancers other than colon, including pancreas, stomach, and esophagus (154), may also be increased with asbestos exposure, but the presence and magnitude of an association with asbestos remain controversial for extrathoracic cancers (154). Routine screening for these cancers is in any case not practical at present.

No prophylactic medication or treatment is currently available to prevent the development or progression of asbestosis or other asbestos-related diseases, once exposure has occurred.

Actions Required after Diagnosis

The diagnosis of asbestosis, in particular, imposes a duty to inform the patient that he or she has a disease that is work-related, to report the disease, and to inform the patient that he or she may have legal or adjudication options for compensation. The role of the physician in this compensation process includes performing an objective evaluation of impairment consistent with the rules of the specific compensation system. Guidelines developed by the American Thoracic Society (3) may be of use and are incorporated into the *AMA Guides to the Evaluation of Permanent Impairment* (157). As in the management of any lung disorder, the physician should also manage the clinical manifestations of the disease and counsel the patient to protect remaining lung function.

The patient with evidence of asbestosis should be considered to be at risk of progressive lung disease, whatever the level of impairment on first encounter. It seems logical that removal from further exposure to asbestos or other significant occupational and environmental exposures may avoid more rapid pro-

gression of lung disease, although specific evidence for this is lacking. However, if such exposures are minimal and are well within occupational guidelines, care must be taken not to deprive the patient of a livelihood for no clinical benefit.

Immunization against pneumococcal pneumonia and annual influenza vaccine should be administered unless contraindicated for other reasons. Effective management of concurrent chronic obstructive pulmonary disease or asthma, if present, may reduce morbidity from mixed disease.

Severe asbestosis is rare in the United States and other countries with generally effective occupational health regulation. Cor pulmonale, secondary polycythemia, and respiratory insufficiency and failure are all treated in the conventional manner in patients with asbestosis.

In the spring of 2000, the Association of Occupational and Environmental Clinics adopted a resolution recommending necessary standards for screening programs (158). This action was taken in response to the proliferation of screening programs undertaken to identify cases for possible legal actions in which counseling and education may be lacking (159), but the recommendations also apply to those conducted for patient care and protection. Their recommendations were consistent with those given above and also emphasized timely physician disclosure of results to the patient, appropriate medical follow-up, and patient education. The National Institute of Occupational Safety and Health has outlined elements of an adequate screening program, with special reference to screening for asbestos-related disorders in currently employed mineworkers, in a white paper produced in 2002 that has received little attention (160). The National Institute for Occupational Safety and Health recommended that such programs should be under the direction of a "qualified physician or other qualified health care provider" knowledgeable in the field and competent to administer it, and documented with written reports to workers and employers (the latter provision that would not necessarily be applicable to workers who had separated from the employer). However, the National Institute for Occupational Safety and Health did not address the issue of counseling in that document or clinical interventions to reduce future risk.

CONCLUSIONS

The diagnosis of nonmalignant asbestos-related disease rests, as it did in 1986, on the essential criteria described: a compatible structural lesion, evidence of exposure, and exclusion of other plausible conditions, with an additional requirement for impairment assessment if the other three criteria suggest asbestos-related disease (2). Each criterion may be satisfied by one of a number of findings or tests. The 2004 criteria are open to future testing modalities if and when they are validated. For example, HRCT has greatly increased the sensitivity of detection and has become a standard method of imaging. Evidence for exposure still rests on the occupational history, the demonstration of asbestos fibers or bodies, or pleural plaques. Impairment evaluation is largely unchanged from 1986 and remains an essential part of the clinical assessment. Potentially confounding conditions, such as idiopathic pulmonary fibrosis, are better understood and many, such as tuberculosis, are less common than in the past so that the clinical picture is less often confusing.

These criteria and the guidelines that support them are compatible with the Helsinki criteria, developed by an expert group in 1997, which represents substantial consensus worldwide (147). The guidelines supporting these criteria will undoubtedly change again in future, but the present guidelines should provide a reliable basis for clinical diagnosis for some years to come.

This statement was developed by an ad hoc subcommittee of the Scientific Assembly on Environmental and Occupational Health of the American Thoracic Society. Members of the committee are as follows:

TEE L. GUIDOTTI, M.D., M.P.H., *Chair*

George Washington University Medical Center, Washington, DC

ALBERT MILLER, M.D.

St. Vincent Catholic Medical Center of New York, Brooklyn-Queens Service Region, Jamaica, NY

DAVID CHRISTIANI, M.D., M.P.H.

Harvard School of Public Health, Boston, MA

GREGORY WAGNER, M.D.

National Institute for Occupational Safety and Health, Morgantown, WV

JOHN BALMES, M.D.

University of California San Francisco, San Francisco, CA

PHILIP HARBER, M.D., M.P.H.

University of California Los Angeles, Los Angeles, CA

CARL ANDREW BRODKIN, M.D., M.P.H.

University of Washington, Seattle, WA

WILLIAM ROM, M.D., M.P.H.

New York University School of Medicine, New York, NY

GUNNAR HILLERDAL, M.D.

Karolinska Institute, Stockholm, Sweden

MICHAEL HARBUT, M.D., M.P.H.

Center for Occupational and Environmental Medicine, Royal Oak, MI

FRANCIS H. Y. GREEN, M.D.

University of Calgary, Calgary, AB, Canada

Acknowledgment: The statement subcommittee thanks the following for contributions, assistance, and suggestions: William Beckett, M.D., M.P.H. (University of Rochester, Rochester, NY) and Jerrold L. Abraham, M.D. (State University of New York, Syracuse, NY). Gross histology and photomicrographs were supplied by Francis H. Y. Green, M.D. Radiographs were supplied by Tee L. Guidotti, M.D., M.P.H.

References

- Committee on Nonoccupational Health Risks of Asbestiform Fibers, Board of Toxicology and Environmental Health Hazards, National Research Council. Asbestiform fibers: nonoccupational health risks. Washington DC: National Academies Press; 1984. p. 24–29.
- American Thoracic Society. The diagnosis of nonmalignant diseases related to asbestos. *Am Rev Respir Dis* 1986;134:363–368.
- American Thoracic Society Ad Hoc Committee on Impairment/Disability Criteria. Evaluation of impairment/disability secondary to respiratory disorders. *Am Rev Respir Dis* 1986;134:1205–1209.
- American Thoracic Society. Lung function testing: selection of reference values and interpretive strategies. *Am Rev Respir Dis* 1991;144:1202–1218.
- Ferris B. Epidemiology standardization project. *Am Rev Respir Dis* 1978;118:1–113.
- Virta RL. Some facts about asbestos. Fact sheet FS-012-01. Reston, VA: U.S. Geologic Survey, U.S. Department of Interior. Available online at <http://pubs.usgs.gov/factsheet/fs012-01/>. Accessed July 29, 2004.
- U.S. Environmental Protection Agency. Region 8 Superfund, Libby. www.epa.gov/region8/superfund/libby/. Accessed July 29, 2004.
- U.S. Department of Labor, Occupational Safety and Health Administration. Safety and health topics: asbestos. Available online at <http://www.osha.gov/SLTC/asbestos>. Accessed July 29, 2004.
- Churg A, Wright JL, Depaoli L, Wiggs B. Mineralogic correlates of fibrosis in chrysotile miners and millers. *Am Rev Respir Dis* 1989; 139:891–896.
- Churg A, Wright J, Wiggs B, DePaoli L. Mineralogic parameters related to amosite asbestos-induced fibrosis in humans. *Am Rev Respir Dis* 1990;142:1331–1336.
- Rom WV. Asbestos-related diseases. In: Environmental and occupational medicine, 3rd ed. Philadelphia, PA: Lippincott-Raven; 1998. p. 349–375.
- Rom WN, Bitterman PB, Rennard SI, Cantin AC, Crystal RG. Characterization of the lower respiratory tract inflammation of non-smoking individuals with interstitial lung disease associated with the chronic inhalation of inorganic dusts. *Am Rev Respir Dis* 1987;137:1429–1434.
- Rom WN, Travis WD, Brody AR. Cellular and molecular basis of the asbestos-related diseases [State of the Art]. *Am Rev Respir Dis* 1991;143:408–422.
- Wright JL, Cagle P, Churg A, Colby TV, Myers J. Diseases of the small airways. *Am Rev Respir Dis* 1992;146:240–262.
- Jaurand MC, Gaudichet A, Atassi K, Sebastien P, Bignon J. Relationship between the number of asbestos fibres and the cellular and enzymatic content of bronchoalveolar fluid in asbestos exposed subjects. *Bull Eur Physiopathol Respir* 1980;16:595–606.
- Bégin R, Cantin A, Berthiaume Y, Boileau R, Peloquin S, Masse S. Airway function in lifetime-nonsmoking older asbestos workers. *Am J Med* 1983;75:631–638.
- Churg A, Wright JL. Small-airway lesions in patients exposed to non-asbestos mineral dusts. *Hum Pathol* 1983;14:688–693.
- Dai J, Gilks B, Price K, Churg A. Mineral dusts directly induce epithelial and interstitial fibrogenic mediators and matrix components in the airway wall. *Am J Respir Crit Care Med* 1998;158:1907–1913.
- De Vuyst P, Karjalainen A, Dumortier P, Pairon J-C, Monso E, Brochard P, Teschler H, Tossavainen A, Gibbs A. Guidelines for mineral fibre analyses in biological samples: report of the ERS Working Group. *Eur Respir J* 1998;11:1416–1426.
- Churg A. Fiber counting and analysis in the diagnosis of asbestos-related disease. *Hum Pathol* 1982;13:381–392.
- Roggli VL, Coin PG, MacIntyre NR, Bell DY. Asbestos content of bronchoalveolar lavage fluid: a comparison of light and scanning electron microscopic analysis. *Acta Cytol* 1994;38:502–510.
- Johnson NF, Haslam PL, Dewar A, Newman-Taylor AJ, Turner-Warwick M. Identification of inorganic dust particles in bronchoalveolar lavage macrophages by energy dispersive x-ray microanalysis. *Arch Environ Health* 1986;41:133–144.
- Morgan A, Holmes A. Concentrations and characteristics of amphibole fibres in the lungs of workers exposed to crocidolite in the British gas-mask factories, and elsewhere, during the Second World War. *Br J Ind Med* 1982;39:62–69.
- Schwartz DA, Galvin JR, Burmeister LF, Merchant RK, Dayton CS, Merchant JA, Hunninghake GW. The clinical utility and reliability of asbestos bodies in bronchoalveolar fluid. *Am Rev Respir Dis* 1991; 144:684–688.
- Churg A, Warnock ML. Analysis of the cores of asbestos bodies from members of the general population: patients with probable low-degree exposure to asbestos. *Am Rev Respir Dis* 1979;120:781–786.
- Dodson RF, Williams MG, Corn CJ, Brollo A, Bianchi C. Asbestos content of lung tissue, lymph nodes, and pleural plaques from former shipyard workers. *Am Rev Respir Dis* 1990;142:843–847.
- Xaubet A, Rodriguez-Roisin R, Bombi JA, Marin A, Roca J, Agustí-Vidal A. Correlation of bronchoalveolar lavage and clinical and functional findings in asbestosis. *Am Rev Respir Dis* 1986;133:848–854.
- Vathesatogkit P, Harkin TJ, Addrizzo-Harris DJ, Bodkin M, Crane M, Rom WN. Clinical correlation of asbestos bodies in bronchoalveolar lavage fluid [abstract]. *Am J Respir Crit Care Med* 2003;167:A684.
- Brodtkin CA, Barnhart S, Anderson G, Checkoway H, Omenn GS, Rosenstock L. Correlation between respiratory symptoms and pulmonary function in asbestos-exposed workers. *Am Rev Respir Dis* 1993; 148:32–37.
- Brodtkin CA, Barnhart S, Checkoway H, Balmes J, Omenn GS, Rosenstock L. Longitudinal pattern of reported symptoms and accelerated ventilatory loss in asbestos-exposed workers. *Chest* 1996;109:120–126.
- Yates DH, Browne K, Stidolph PN, Neville E. Asbestos-related bilateral diffuse pleural thickening: natural history of radiographic and lung function abnormalities. *Am J Respir Crit Care Med* 1996;153:301–306.
- Committee on Occupational and Environmental Health of the American Lung Association of San Diego and Imperial Counties. Taking the occupational history. *Ann Intern Med* 1983;99:641–651.
- Welch LS, Michaels D, Zoloth SR. The national sheet metal worker asbestos disease screening program: radiologic findings. *Am J Ind Med* 1994;25:635–648.
- Epler GR, Gerald MX, Gaensler EA, Carrington CB. Asbestos-related disease from household exposure. *Respiration (Herrlisheim)* 1980;39: 229–240.
- Weill H, Waggenspack C, Bailey W, Ziskin M, Rossiter C. Radiographic

- and physiologic patterns among workers engaged in manufacture of asbestos cement products. *J Occup Med* 1973;15:248–252.
36. Markowitz SB, Marabia A, Lillis R, Miller A, Nicholson WJ, Levin S. Clinical predictors of mortality from asbestosis in the North American Insulator Cohort, 1981–1991. *Am J Respir Crit Care Med* 1997;156:101–108.
 37. Murphy RL Jr, Gaensler EA, Holford SK, Del Bono EA, Epler G. Crackles in the early detection of asbestosis. *Am Rev Respir Dis* 1984;129:375–379.
 38. International Labour Office. International classification of radiographs of pneumoconioses. Geneva, Switzerland: International Labour Organization; 2003.
 39. Harkin TJ, McGuinness G, Goldring R, Parker JE, Crane M, Naidich DP. Differentiation of the ILO boundary chest roentgenograph (0/1 to 1/0) in asbestosis by high-resolution computed tomography scan, alveolitis, and respiratory impairment. *J Occup Environ Med* 1996;38:46–52.
 40. Kipen HM, Lillis R, Suzuki Y, Valciukas JA, Selikoff IJ. Pulmonary fibrosis in asbestos insulation workers with lung cancer: a radiological and histopathological evaluation. *Br J Ind Med* 1987;44:96–100.
 41. Epler GR, McLoud TC, Gaensler EA, Mikus JP, Carrington CB. Normal chest roentgenograms in chronic diffuse infiltrative lung disease. *N Engl J Med* 1978;298:934–939.
 42. Aberle DR, Gamsu G, Ray CS. High-resolution CT of benign asbestos-related diseases: clinical and radiographic correlation. *Am J Roentgenol* 1988;151:883–891.
 43. Schwartz DA, Galvin JR, Yagla SJ, Speakman SB, Merchant JA, Hunninghake GW. Restrictive lung function and asbestos-induced pleural fibrosis: a quantitative approach. *J Clin Invest* 1993;91:2685–2692.
 44. Lee YC, Rynnion CK, Pang SC, de Klerk NH, Musk AW. Increased body mass index is related to apparent circumscribed pleural thickening on plain chest radiographs. *Am J Ind Med* 2001;39:112–116.
 45. Ameille J, Brochard, Brechot JM, Pascano T, Cherin A, Raix A, Frey M, Bignon J. Pleural thickening: a comparison of oblique chest radiographs and high-resolution computed tomography in subjects exposed to low levels of asbestos pollution. *Int Arch Occup Environ Health* 1993;64:545–548.
 46. Genevois PA, De Vuyst P, Dedeire S, Cosaert J, Vande Weyer R, Sturyven J. Conventional and high-resolution CT in asymptomatic asbestos-exposed workers. *Acta Radiol* 1994;35:226–229.
 47. Genevois PA, de Maertaeler V, Madani A, Winant C, Sergent G, De Vuyst P. Asbestosis, pleural plaques and diffuse pleural thickening: three distinct benign responses to asbestos exposure. *Eur Respir J* 1998;11:1021–1027.
 48. Neri S, Borashi P, Antonelli A, Falaschi F, Baschieri L. Pulmonary function, smoking habits, and high resolution computed tomography (HRCT) early abnormality of lung and pleural fibrosis in shipyard workers exposed to asbestos. *Am J Ind Med* 1996;30:588–595.
 49. Gamsu G, Salmon CJ, Warnock ML, Blanc PD. CT quantification of interstitial fibrosis in patients who have asbestosis: a comparison of two methods. *AJR Am J Roentgenol* 1995;164:63–68.
 50. Staples CA, Gamsu G, Ray CS, Webb WR. High resolution computed tomography and lung function in asbestos-exposed workers with normal chest radiographs. *Am Rev Respir Dis* 1989;139:1502–1508.
 51. Sargent EN, Boswell WD Jr, Ralls PW, Markovitz A. Subpleural fat pads in patients exposed to asbestos: distinction from non-calcified pleural plaques. *Radiology* 1984;152:273–277.
 52. Staples CA. Computed tomography in the evaluation of benign asbestos-related disorders. *Radiol Clin North Am* 1992;30:1191–1207.
 53. Webb WR, Müller NL, Naidich DP. High-resolution CT of the lung, 3rd ed. Philadelphia: Lippincott Williams & Wilkins; 2001. Chapter 4, Diseases characterized primarily by linear and reticular opacities. p. 236–251.
 54. Kraus T, Raithel HJ, Lehnert G. Computer-assisted classification system for chest X-ray and computed tomography findings in occupational lung disease. *Int Arch Occup Environ Health* 1997;69:482–486.
 55. Van Cleemput J, De Raeye H, Verschakelen JA, Rombouts J, Lacquet LM, Nemery B. Surface of localized pleural plaques quantitated by computed tomography scanning: no relation with cumulative asbestos exposure and no effect on lung function. *Am J Respir Crit Care Med* 2001;163:705–710.
 56. De Vuyst P, Jedwab J, Dumortier P, Vandermoten G, Vande Weyer R, Yernault JC. Asbestos bodies in bronchoalveolar lavage. *Am Rev Respir Dis* 1982;126:972–976.
 57. De Vuyst P, Dumortier P, Moulin E, Yourassowsky N, Roomans P, de Francquen P, Yernault JC. Asbestos bodies in bronchoalveolar lavage reflect lung asbestos body concentration. *Eur Respir J* 1988;1:362–367.
 58. Karjalainen A, Antilla S, Mantyla T, Taskinen E, Kyyronen P, Tukiainen P. Asbestos bodies in bronchoalveolar lavage fluid in relation to occupational history. *Am J Ind Med* 1994;26:645–654.
 59. De Vuyst P, Dumortier P, Moulin E, Yourassowsky N, Yernault JC. Diagnostic value of asbestos bodies in bronchoalveolar lavage fluid. *Am Rev Respir Dis* 1987;136:1219–1224.
 60. Rom WN, Churg A, Leapman R, Fiori C, Swyt C. Evaluation of alveolar macrophage particle burden in individuals occupationally exposed to inorganic dusts. *J Aerosol Med* 1990;3:S43–S56.
 61. Sartorelli P, Scancarello G, Romeo R, Marcianò G, Rottoli P, Arcangeli G, Palmi S. Asbestos exposure assessment by mineralogical analysis of bronchoalveolar lavage fluid. *J Occup Environ Med* 2001;43:872–881.
 62. Sebastien P, Armstrong B, Monchoux G, Bignon J. Asbestos bodies in bronchoalveolar lavage fluid and in lung parenchyma. *Am Rev Respir Dis* 1988;137:75–78.
 63. Teschler H, Heinz-Friedrichs K, Hoheisel GR, Wick G, Soltner U, Thompson AB, Konietzko N, Costabel U. Asbestos fibers in bronchoalveolar lavage and lung tissue of former asbestos workers. *Am J Respir Crit Care Med* 1994;149:641–645.
 64. Craighead JE, Abraham JL, Churg A, Green FHY, Kleinerman J, Pratt PC, Seemayer TA, Vallyathan V, Weill H. The pathology of asbestos-associated diseases of the lungs and pleural cavities: diagnostic criteria and proposed grading schema. Report of the Pneumoconiosis Committee of the College of American Pathologists and the National Institute for Occupational Safety and Health. *Arch Pathol Lab Med* 1982;106:543–596.
 65. Green FH, Attfield M. Pathology standards for asbestosis. *Scand J Work Environ Health* 1983;9:162–168.
 66. Green FHY, Harley R, Vallyathan V, Althouse R, Fick G, Dement J, Mitha R, Pooley F. Exposure and mineralogic correlates of pulmonary fibrosis in chrysotile asbestos workers. *Occup Environ Med* 1997;54:549–559.
 67. Barnhart S, Thornquist M, Omenn GS, Goodman G, Feigl P, Rosenstock L. The degree of roentgenographic parenchymal opacities attributable to smoking among asbestos-exposed subjects. *Am Rev Respir Med* 1990;141:1102–1106.
 68. Zitting AJ, Karjalainen A, Impivaara O, Kuusela T, Mäki J, Tossavainen A, Järvisalo J. Radiographic small lung opacities and pleural abnormalities in relation to smoking, urbanization status and occupational asbestos exposure in Finland. *J Occup Environ Med* 1996;38:602–609.
 69. Lillis R, Selikoff IJ, Lerman Y, Seidman H, Gelb SK. Asbestosis: interstitial pulmonary fibrosis and pleural fibrosis in a cohort of asbestos insulation workers: influence of cigarette smoking. *Am J Ind Med* 1986;10:459–470.
 70. Ehrlich R, Lillis R, Chan E, Nicholson WJ, Selikoff IJ. Long-term radiological effects of short-term exposure to amosite among factory workers. *Br J Ind Med* 1992;49:268–275.
 71. Green RA, Dimcheff DG. Massive bilateral upper lobe fibrosis secondary to asbestos exposure. *Chest* 1974;65:52–55.
 72. Hillerdal G. Pleural and parenchymal fibrosis mainly affecting the upper lung in persons exposed to asbestos. *Respir Med* 1990;84:129–134.
 73. Morgan A, Holmes A. Distribution and characteristics of amphibole asbestos fibres, measured with the light microscope, in the left lung of an insulation worker. *Br J Ind Med* 1983;40:45–50.
 74. Miller A, Lillis R, Godbold J, Chan E, Selikoff IJ. Relationship of pulmonary function to radiographic interstitial fibrosis in 2,611 long-term asbestos insulators: an assessment of the International Labour Office profusion score. *Am Rev Respir Dis* 1992;145:263–270.
 75. Selikoff IJ, Churg J, Hammond EC. Asbestos exposure and neoplasia. *JAMA* 1964;188:22–26.
 76. Schwartz DA, Fuortes LJ, Galvin JR, Burmeister LF, Schmidt LE, Leistikow BN, LaMarte FP, Merchant JA. Asbestos-induced pleural fibrosis and impaired lung function. *Am Rev Respir Dis* 1990;141:321–326.
 77. Rom WN. Accelerated loss of lung function and alveolitis in a longitudinal study of non-smoking individuals with occupational exposure to asbestos. *Am J Ind Med* 1992;21:835–844.
 78. Becklake M, Case B. Fiber burden and asbestos-related lung disease: determinants of dose–response relationships. *Am J Respir Crit Care Med* 1994;150:1488–1492.
 79. Roggli VL, Pratt PC. Numbers of asbestos bodies on iron-stained sections in relation to asbestos body counts in lung tissue digests. *Hum Pathol* 1984;14:355–361.
 80. Dodson RF, Williams MG Jr, O'Sullivan MF, Corn CJ, Greenberg SD, Hurst GA. A comparison of the ferruginous and uncoated fiber content in the lungs of former asbestos workers. *Am Rev Respir Dis* 1985;132:143–147.

81. Seal RME. Current views on pathological aspects of asbestosis: the unresolved questions and problems. In: Wagner JC, editor. Biological effects of mineral fibers. Lyon, France: International Agency for Research on Cancer; 1980. p. 217–235.
82. Miller A, Langer AM, Tierstein AS, Selikoff IJ. "Nonspecific" interstitial pulmonary fibrosis: association with asbestos fibers detected by electron microscopy. *N Engl J Med* 1975;292:91–94.
83. Hnizdo E, Sullivan P, Bang KM, Wagner GR. Association between chronic obstructive pulmonary disease and employment by industry and occupational in the US population: a study of data from the Third National Health and Nutrition Examination Survey. *Am J Epidemiol* 2002;156:738–746.
84. Hammar SP, Hallman KO. Localized inflammatory pulmonary disease in subjects occupationally exposed to asbestos. *Chest* 1993;103:1792–1799.
85. Al-Jarad N, Wilkinson P, Pearson MC, Rudd RM. A new high resolution computed tomography scoring system for pulmonary fibrosis, pleural disease, and emphysema in patients who have asbestos related disease. *Br J Ind Med* 1992;49:73–84.
86. Webb WR, Cooper C, Gamsu G. Interlobar pleural plaque mimicking a lung nodule in a patient with asbestos exposure. *J Comput Assist Tomogr* 1983;7:135–136.
87. Hillerdal G, Ozesmi M. Benign asbestos pleural effusion: 73 exudates in 60 patients. *Eur J Respir Dis* 1987;71:113–121.
88. Epler GR, Gaensler EA. Prevalence of asbestos pleural effusion in a working population. *JAMA* 1982;247:617–622.
89. Robinson BWS, Musk AW. Benign asbestos pleural effusion: diagnosis and course. *Thorax* 1981;36:896–900.
90. Lilis R, Lerman Y, Selikoff IJ. Symptomatic benign pleural effusions among asbestos insulation workers: residual radiographic abnormalities. *Br J Ind Med* 1988;45:443–449.
91. Miller A, Miller JA. Diffuse pleural thickening superimposed on circumscribed pleural thickening related to asbestos exposure. *Am J Ind Med* 1993;23:859–871.
92. Miller A. Chronic pleuritic pain in four patients with asbestos induced pleural fibrosis. *Br J Ind Med* 1990;47:147–153.
93. Fielding DI, McKeon JL, Oliver WA, Matar K, Brown IG. Pleurectomy for persistent pain in benign asbestos-related disease. *Thorax* 1995;50:181–183.
94. Rogan WJ, Gladen BC, Ragan NB, Anderson HA. US prevalence of occupational pleural thickening: a look at x-rays from the First National Health and Nutrition Examination Survey. *Am J Epidemiol* 1987;126:893–900.
95. Miller JA, Zurlo JV. Asbestos plaques in a typical veteran's hospital population. *Am J Ind Med* 1996;30:726–729.
96. Bégin R, Boctor M, Bergeron D, Cantin A, Berthiaume Y, Peloquin S, Bisson G, Lamoureux G. Radiographic assessment of pleuropulmonary disease in asbestos workers: posteroanterior, four view films, and computed tomograms of the thorax. *Br J Ind Med* 1984;41:373–383.
97. Churg A. The pathogenesis of pleural plaques. *Indoor Built Environ* 1997;6:73–78.
98. Taskinen E, Ahlmon K, Wiikeri M. A current hypothesis of the lymphatic transport of inspired dust to the parietal pleura. *Chest* 1973;64:193–196.
99. Churg A, Vedal S. Fiber burden and patterns of asbestos-related disease in workers with heavy mixed amosite and chrysotile exposure. *Am J Respir Crit Care Med* 1994;150:663–669.
100. Churg A, Wright JL, Vedal S. Fiber burden and patterns of asbestos-related disease chrysotile miners and millers. *Am Rev Respir Dis* 1993;148:25–31.
101. Kishimoto T, Ono T, Okada K, Ito H. Relationship between number of asbestos bodies in autopsy lung and pleural plaques on chest x-ray film. *Chest* 1989;95:549–552.
102. Sison RF, Hruban RH, Moore GW, Kuhlman JE, Wheeler PS, Hutchins GM. Pulmonary disease associated with pleural "asbestos" plaques. *Chest* 1989;95:831–835.
103. Lilis R, Miller A, Godbold J, Chan E, Selikoff IJ. Radiographic abnormalities in asbestos insulators: effects of duration from onset of exposure and smoking; relationships of dyspnea with parenchymal and pleural fibrosis. *Am J Ind Med* 1991;20:1–15.
104. Schwartz DA. New developments in asbestos-induced pleural disease. *Chest* 1991;99:191–198.
105. Hillerdal G, Henderson DW. Asbestos, asbestosis, pleural plaques and lung cancer. *Scand J Work Environ Health* 1997;23:93–103.
106. Hillerdal G. Pleural plaques and the risk for bronchial carcinoma and mesothelioma. *Chest* 1994;105:144–150.
107. Jarvold B, Sanden A. Pleural plaques and respiratory function. *Am J Ind Med* 1986;10:419–426.
108. Hjørtberg U, Ørbaek P, Aborelius M Jr, Ranstam J, Welinder H. Railroad workers with pleural plaques. I. Spirometric and nitrogen washout investigation on smoking and nonsmoking asbestos-exposed workers. *Am J Ind Med* 1988;14:635–641.
109. Oliver LC, Eisen EA, Greene R, Sprince NL. Asbestos-related pleural plaques and lung function. *Am J Ind Med* 1988;14:649–656.
110. Bourbeau J, Ernst P, Chrome J, Armstrong B, Becklake MR. The relationship between respiratory impairment and asbestos-related pleural abnormality in an active work force. *Am Rev Respir Dis* 1990;142:837–842.
111. Ohlson G, Rydman T, Sundell L, Bodin L, Hogstedt C. Decreased lung function in long-term asbestos cement workers: a cross-sectional study. *Am J Ind Med* 1984;5:359–366.
112. Lilis R, Miller A, Godbold J, Chan E, Selikoff IJ. Pulmonary function and pleural fibrosis: quantitative relationships with an integrative index of pleural abnormalities. *Am J Ind Med* 1991;29:145–161.
113. Ohlson C-G, Bodin L, Rydman T, Hogstedt C. Ventilatory decrements in former asbestos cement workers: a four year follow up. *Br J Ind Med* 1985;42:612–616.
114. Miller A, Bhuptani A, Sloane MF, Brown LK, Teirstein AS. Cardiopulmonary responses to incremental exercise in patients with asbestos-related pleural thickening and normal or slightly abnormal lung function. *Chest* 1993;103:1045–1050.
115. Hillerdal G. Non-malignant asbestos pleural disease. *Thorax* 1981;36:669–675.
116. Finkelstein MM. A study of dose-response relationships for asbestos associated disease. *Br J Ind Med* 1985;42:319–325.
117. Gibbs AR, Stephens M, Griffiths DM, Blight B, Pooley FD. Fibre distribution in the lungs and pleura of subjects with asbestos related diffuse pleural fibrosis. *Br J Ind Med* 1991;48:762–770.
118. Stephens M, Gibbs AR, Pooley FD, Wagner JC. Asbestos induced diffuse pleural fibrosis: pathology and mineralogy. *Thorax* 1987;42:583–588.
119. Kee ST, Gamsu G, Blanc P. Causes of pulmonary impairment in asbestos-exposed individuals with diffuse pleural thickening. *Am J Respir Crit Care Med* 1996;154:789–793.
120. Green RA, Dimcheff DG. Massive bilateral upper lobe fibrosis secondary to asbestos exposure. *Chest* 1974;65:52–55.
121. Hillerdal G. Pleural and parenchymal fibrosis mainly affecting the upper lobes in persons exposed to asbestos. *Respir Med* 1990;84:129–134.
122. Miller A, Teirstein AS, Selikoff IJ. Ventilatory failure due to asbestos pleurisy. *Am J Med* 1983;75:911–919.
123. Hanke R. Rundatelektasen (Kugel- und Walzenatelektasen): ein Beitrag zur differential diagnose intrapulmonaler Rundherde. *Fortschr Roentgenstr* 1971;114:164–183.
124. Hillerdal G. Rounded atelectasis: clinical experience with 74 patients. *Chest* 1989;95:836–841.
125. Blesovsky A. The folded lung. *Br J Dis Chest* 1996;60:19–22.
126. Gamsu G, Aberle DR, Lynch D. Computed tomography in the diagnosis of asbestos-related thoracic disease. *J Thorac Imaging* 1989;4:61–67.
127. Kennedy SM, Vedal S, Müller N, Kassam A, Chan-Yeung M. Lung function and chest radiograph abnormalities among construction insulators. *Am J Ind Med* 1991;20:673–684.
128. Jodoïn G, Gibbs GW, Macklem PT, McDonald JC, Becklake MR. Early effects of asbestos exposure on lung function. *Am Rev Respir Dis* 1971;104:525–535.
129. Mohsenifar Z, Jasper AJ, Mahrer T, Koerner SK. Asbestos and airflow limitation. *J Occup Med* 1985;28:817–820.
130. Wright JL, Churg A. Morphology of small airways disease induced by asbestos exposure. *Hum Pathol* 1984;15:68–74.
131. Fournier-Massey G, Becklake MR. Pulmonary function profiles in Quebec asbestos workers. *Bull Physiopathol Respir (Nancy)* 1975;11:429–445.
132. Rodriguez-Roisin R, Merchant JE, Cochrane GM, Hickey BP, Turner-Warwick M, Clark TJ. Maximal expiratory flow volume curves in workers exposed to asbestos. *Respiration (Herrlisheim)* 1980;39:58–65.
133. Wang XR, Yano E, Nonaka K, Wang M, Wang Z. Pulmonary function of nonsmoking female asbestos workers without radiographic signs of asbestosis. *Arch Environ Health* 1998;53:292–298.
134. Nkade T. Decline in annual lung function in workers exposed to asbestos with and without pre-existing fibrotic changes on chest radiography. *Occup Environ Med* 1995;52:368–373.
135. Wang XR, Christiani DC. Respiratory symptoms and functional status in workers exposed to silica, asbestos, and coal mine dusts. *J Occup Environ Med* 2000;42:1076–1084.

136. Kilburn K, Warshaw RH, Einstein K, Bernstein J. Airway disease in non-smoking asbestos workers. *Arch Environ Health* 1985;40:293–295.
137. Griffith DE, Garcia JGN, Dodson RF, Levin JL, Kronenberg RS. Airflow obstruction in nonsmoking, asbestos- and mixed dust-exposed workers. *Lung* 1993;171:213–224.
138. Bégin R, Filion R, Ostiguy G. Emphysema in silica- and asbestos-exposed workers seeking compensation: CT scan study. *Chest* 1995;108:647–655.
139. Wright JL, Churg A. Severe diffuse small airways disease in long-term chrysotile miners. *Br J Ind Med* 1985;42:556–559.
140. Pinkerton KE, Green FHY, Saiki C, Vallyathan V, Plopper CG, Gopal V, Hung D, Bahne EB, Lin SS, Menache MG, et al. Distribution of particulate matter and tissue remodeling in the human lung. *Environ Health Perspect* 2000;108:1063–1069.
141. Siracusa A, Forcina A, Volpi R, Mollicella E, Cicioni C, Fiordi T. An 11-year longitudinal study of the occupational dust exposure and lung function of polyvinyl chloride, cement and asbestos cement factory workers. *Scand J Work Environ Health* 1988;14:181–188.
142. Schwartz DA, Davis CS, Merchant JA, Bunn WB, Galvin JR, van Fossen DS, Dayton CS, Hunninghake GW. Longitudinal changes in lung function among asbestos-exposed workers. *Am J Respir Crit Care Med* 1994;150:1243–1249.
143. Dujč Ž, Tocilj J, Šarič M. Early detection of interstitial lung disease in asbestos exposed non-smoking workers by mid-expiratory flow rate and high resolution computed tomography. *Br J Ind Med* 1991;48:663–664.
144. Barnhart S, Hudson LD, Mason SE, Pierson DJ, Rosenstock L. Total lung capacity: an insensitive measure of impairment in patients with asbestosis and chronic obstructive pulmonary disease? *Chest* 1988;93:299–302.
145. Kilburn K, Miller A, Warshaw RH. Measuring lung volumes in advanced asbestosis: comparability of plethysmographic and radiographic versus helium rebreathing and single breath methods. *Respir Med* 1993;87:115–120.
146. Wright JL, Tron V, Wiggs B, Churg A. Cigarette smoke potentiates asbestos-induced airflow abnormalities. *Exp Lung Res* 1988;14:537–548.
147. Anonymous. Asbestos, asbestosis, and cancer: the Helsinki criteria for diagnosis and attribution. *Scand J Work Environ Health* 1997;23:311–316.
148. Ohar J, Sterling DA, Bleecker E, Donohue J. Changing patterns in asbestos-induced lung disease. *Chest* 2004;125:744–753.
149. Osinubi Y, Afilaka AA, Doucette J, Golden A, Soriano T, Rovner E, Anselm E. Study of smoking behavior in asbestos workers. *Am J Ind Med* 2002;41:62–69.
150. Ross RM. The clinical diagnosis of asbestosis in this century requires more than a chest radiograph. *Chest* 2003;124:1120–1128.
151. Homa DM, Garabrant DH, Gillespie BW. A meta-analysis of colorectal cancer and asbestos exposure. *Am J Epidemiol* 1994;139:1210–1222.
152. U.S. Preventive Services Task Force. Lung cancer screening: recommendation statement. *Ann Intern Med* 2004;140:738–739.
153. Humphrey LL, Teutsch S, Johnson M. Lung cancer screening with sputum cytologic examination, chest radiography, and computed tomography: an update for the US Preventive Services Task Force. *Ann Intern Med* 2004;140:740–753.
154. Goodman M, Morgan RW, Ray R, Malloy CD, Zhao K. Cancer in asbestos-exposed occupational cohorts: a meta-analysis. *Cancer Causes Control* 1999;10:453–465.
155. Smith RA, Mettlin CJ, Davis KJ, Eyre H. American Cancer Society guidelines for the early detection of cancer. *CA Cancer J Clin* 2000;50:34–49.
156. Seidman H, Selikoff IJ, Gelb SK. Mortality experience of amosite asbestos factory workers: dose–response relationships 5 to 40 years after onset of short-term work exposure. *Am J Ind Med* 1986;10:479–514.
157. Cocchiarella L, Andersson GBJ, editors. Guides to the evaluation of permanent impairment. Chicago, IL: AMA Press; 2001. p. 87–115.
158. Association of Occupational and Environmental Clinics. Asbestos screening (resolution adopted Spring 2000). Available online at www.aocc.org/asbestos-screen.htm. Accessed July 29, 2004.
159. Egilman D, Bohme SR. Attorney-directed screenings can be dangerous. *Am J Ind Med* 2004;45:305–307.
160. National Institute for Occupational Safety and Health. Comments to DOL: Comments of the National Institute for Occupational Safety and Health on the Mine Safety and Health Administration Advanced Notice of Proposed Rulemaking on Measuring and Controlling Asbestos Exposure, 30 CFR Parts 58 and 72, 2002.