Intracardiac echo (ICE) for ablation of ventricular arrhythmias

Jacob S. Koruth, MD
Director, Experimental Laboratory
Helmsley Electrophysiology Center,
Mount Sinai Medical Center,
New York, NY

Jacob.koruth@mountsinai.org

Mount Sinai Hospital

Disclosures

- Research Grants: Biosense Webster, Iowa approach, Vytronus , Medlumics , Luxcath , Abbott, Cardionext:
- Biosense Webster, Abbott, ACT - Consultant
- Iowa approach, Medtronic- Advisory board

Images: Helmsley Electrophysiology Service at
Mount Sinai Medical Center
V Y Reddy, S Dukkipati, W. Whang, M. Miller,
A Sofi, S Choudhry

Utility of ICE for VA
(Above and beyond that of Mapping Systems and X-ray)

- Pre ablation :
  - Endocardial thrombus identification, LV function, Scar/etiology assessment
  - Trans-septal access (visualization of interatrial septum and location of puncture)
  - Creation of anatomical boundaries and identifying critical structures

- Ablation :
  - Catheter tissue contact
  - Lesion formation, Steam pop
  - Continued assessment of LV function , pLVAD position, PEA after defibrillation
  - Management of tamponade

Types of Intracardiac Echo (ICE)

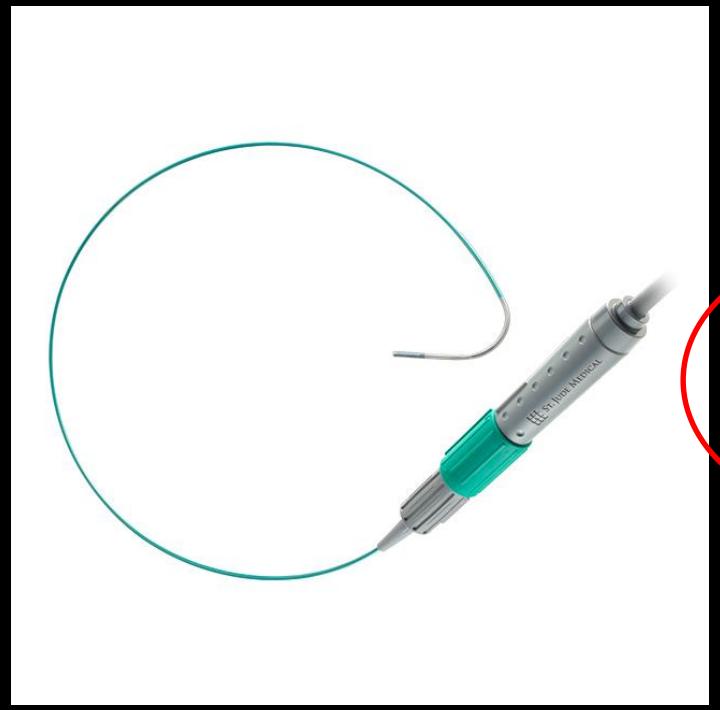

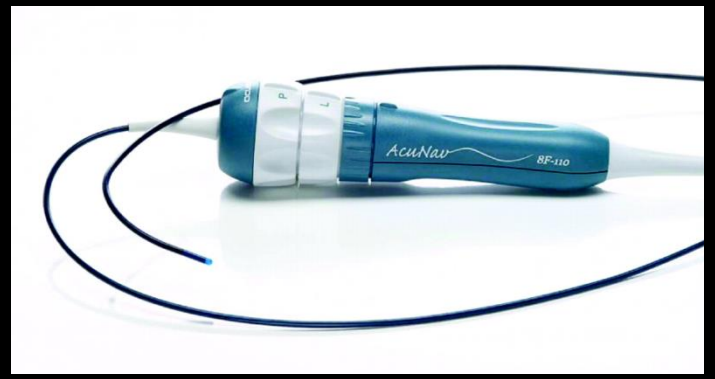

Device name	Company	Features
UltraICE	Boston Scientific	9-Fr nonsteerable rotational motor-driven grayscale-only.
AcuNav	Siemens, Biosense Webster	Side-looking 64-element phased-array 4-way steerability, 8-Fr and 10-Fr, grayscale, color Doppler, tissue Doppler.
ViewFlex Xtra	St. Jude Medical	Side-looking 64-element phased-array 4-way steerability, 8-Fr, grayscale, color Doppler.
EP Med ViewFlex	St. Jude Medical	Run side-looking 64-element catheter on the ViewMate scanner, 10-Fr introducer, 2-way flex color Doppler, grayscale, tissue Doppler 8 to 2 MHz.
ClearICE	St. Jude Medical	Derived from the hockey stick, 64-element side-looking highly steerable 4-way side-looking array with 2 sets of electrodes for integration of 3D localization with EnSite NavX, runs on the GE Vivid/scanner, grayscale, tissue Doppler, synchronization mapping, 2D speckle tracking.
Soundstar	Biosense Webster	10-Fr device with integrated ultrasound array with the Carto magnetic sensor in the tip, allows for integration of ICE and 3D map.

Hijazi ZM, Shivkumar K. Circulation. 2009;119:587-596.

Step-by-Step Workflow for Ventricle

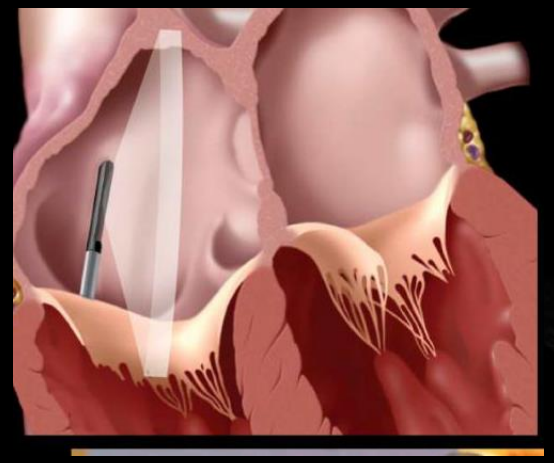

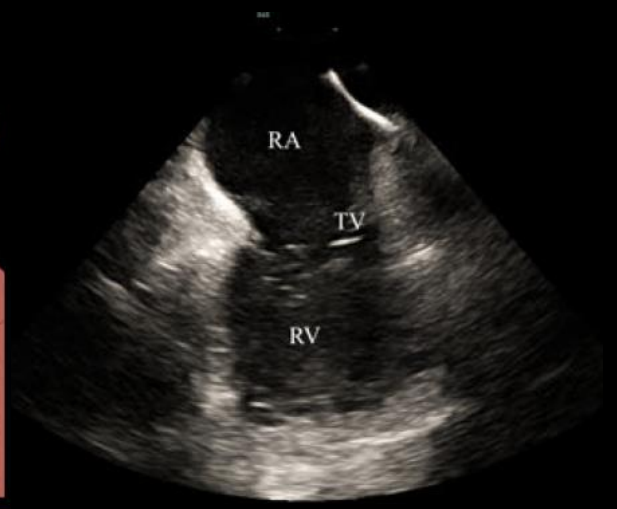

- Home view

- Anteriorly flex (TV in view)
- Advance gently into the RV
- Release deflection - view inferior RV

Enriquez A, Garcia F. Circulation. 2018 May 22;137(21):2278-229

Step-by-Step Workflow for Ventricle

- Clock- Septum & LV Apex

Scan the heart to look

- At valves
- LV function
- Presence/absence of pericardial effusion

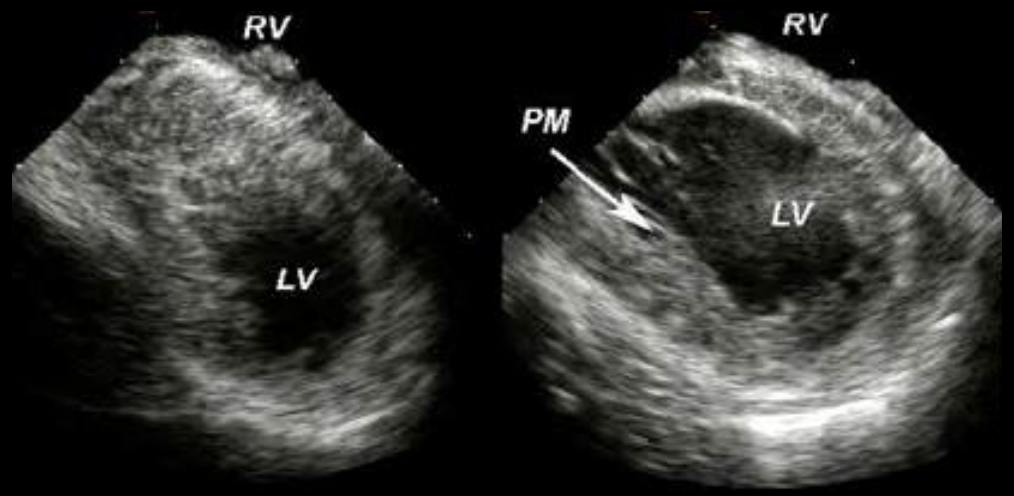

- Clock- PM papillary, Septum and LV Anterior wall

- Clock- AL papillary, LV Inf Wall, Mitral valve

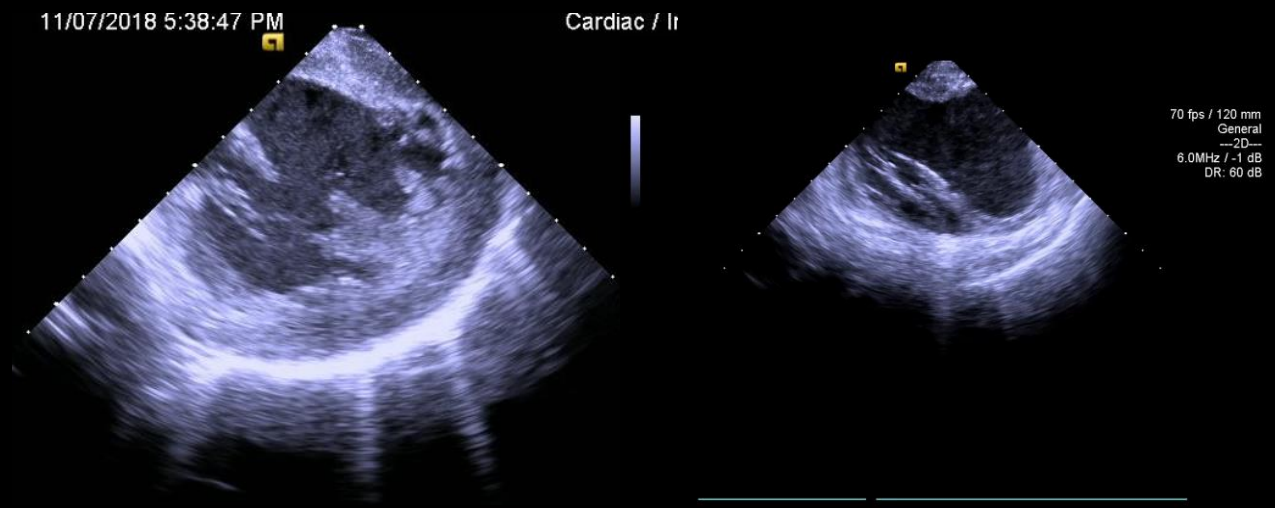

- Clock- LVOT/Aortic root short axis
- LAA and LSPV, left main artery

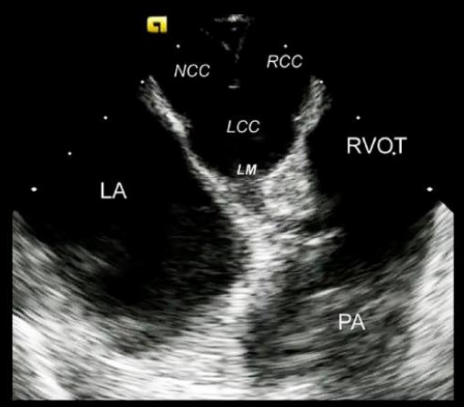

- Advance into RVOT- long axis RVOT& PV
- Clock- Aorta, Lateral RV

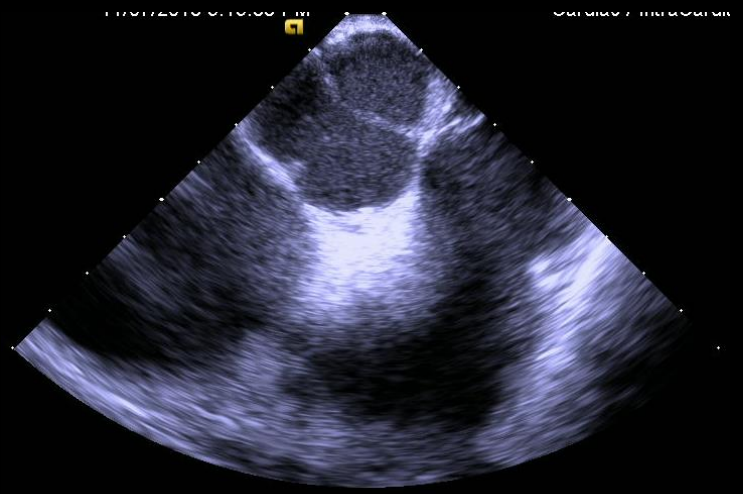

Anteriorly biased Transseptal access

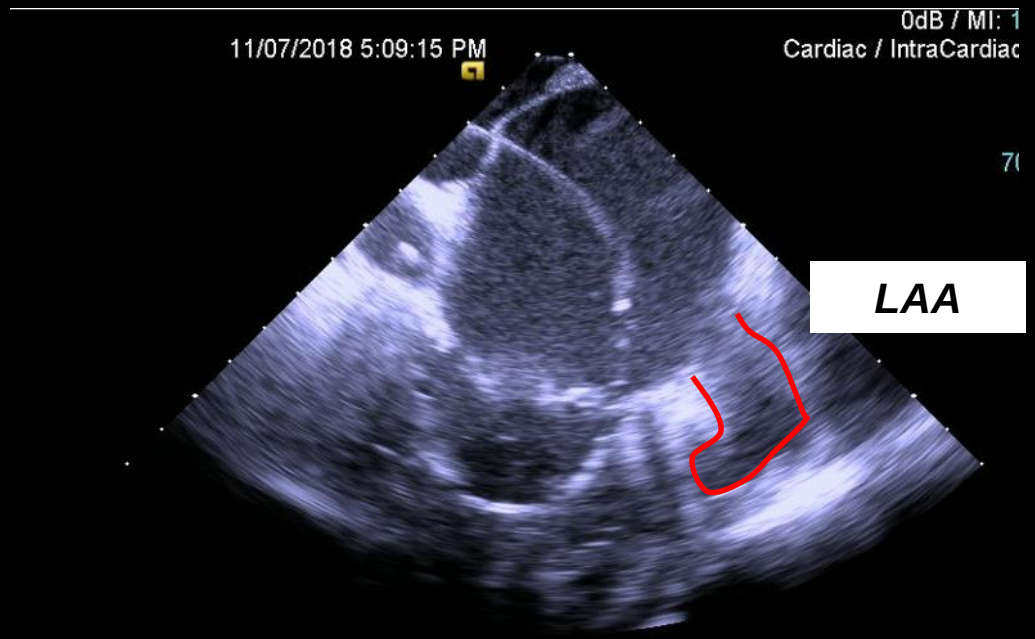

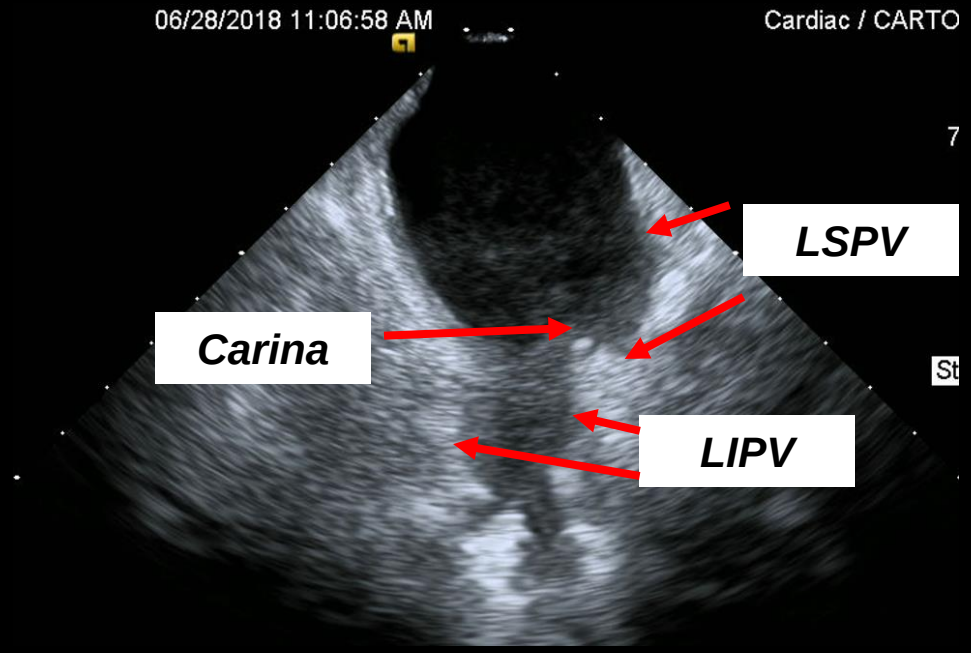

Utility of ICE for VA
(above and beyond that of mapping systems and X-ray)

- For Scar based VT
  - Non-ischemic CMP: Identification of mid-myocardial scar, epicardial scar
  - Ischemic CMP- Identifying transmural scar, wall motion abnormalities

  - Identifying endocavitary structures- esp infarcted papillary muscles
  - Monitoring long RF applications, (use of HNS)- looking out for myocardial steam formation (pre-pop)

Incorporation of Scar into map

- Most useful when scar is mid-myocardial

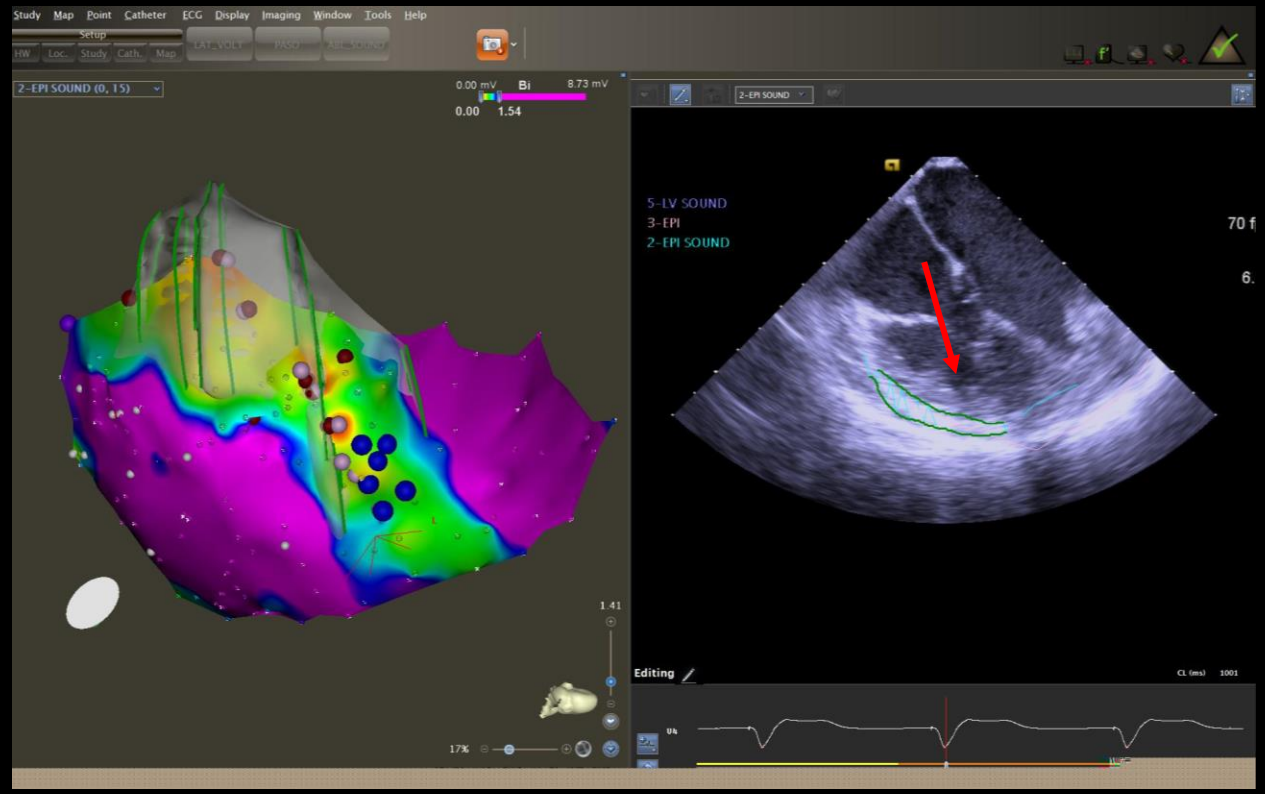

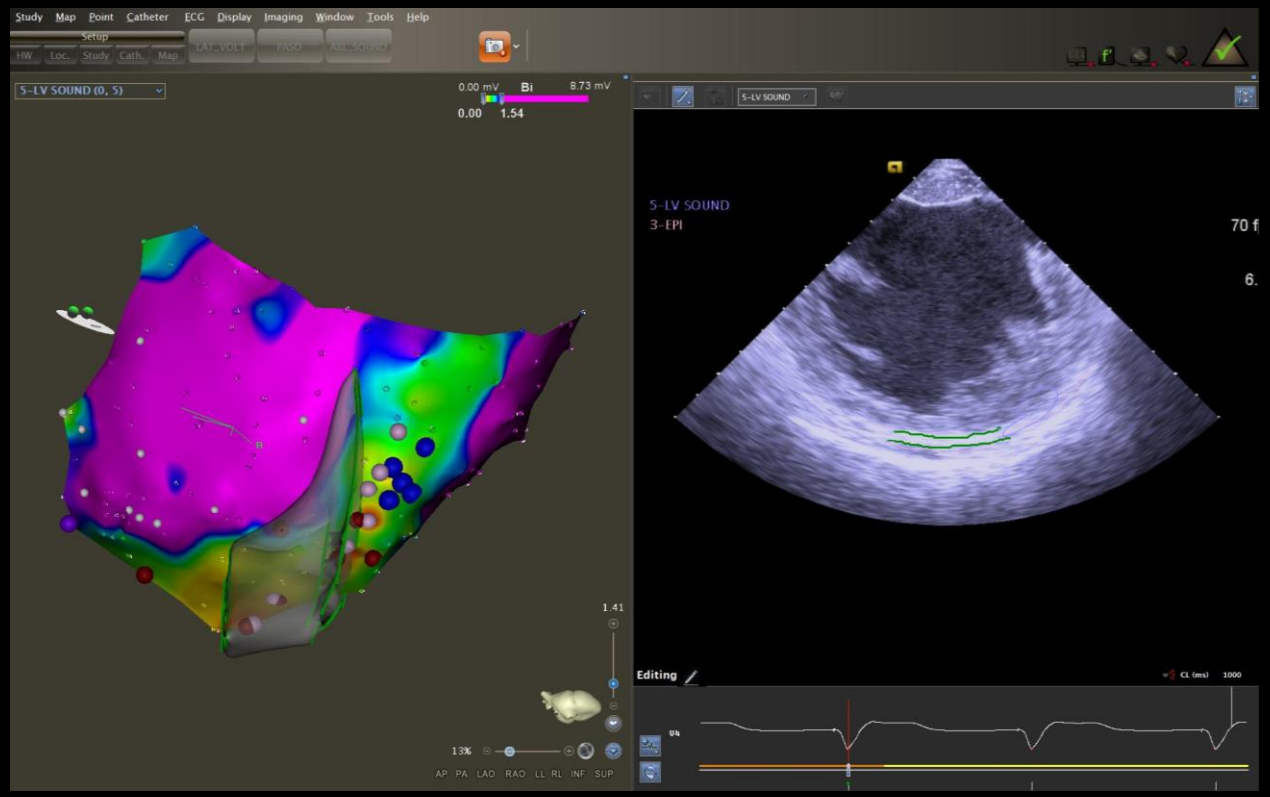

Mid myocardial scar identification can allow directed approaches such a long duration ablation to target such scar

Incorporation of Scar into Map

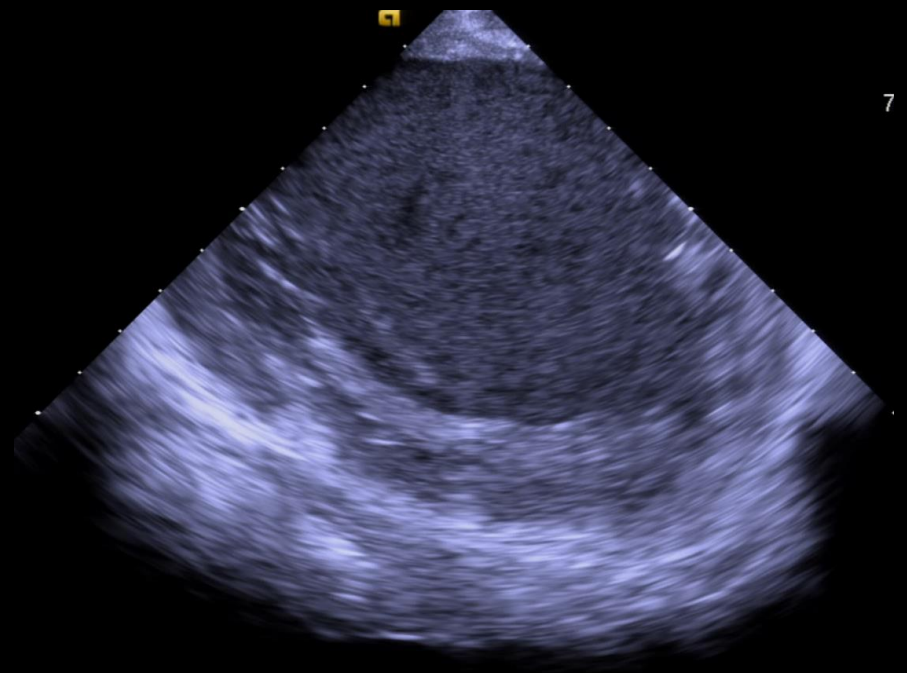

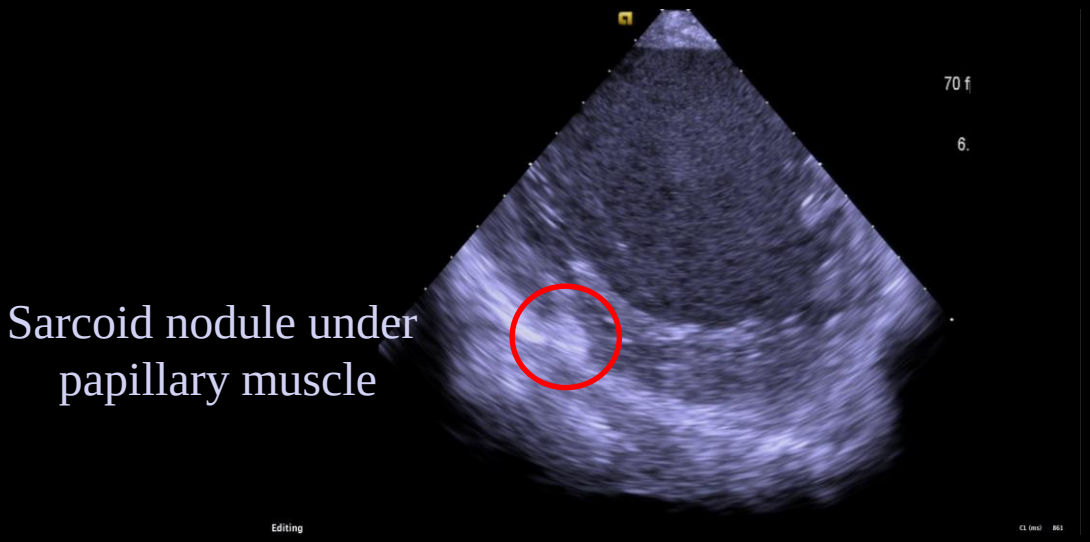

Sarcoid nodule under papillary muscle

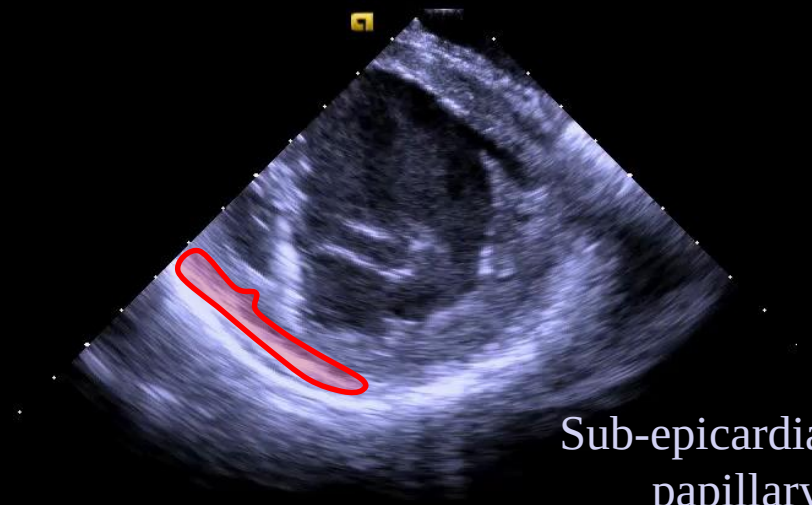

Sub-epicardial scar under papillary muscle

Identification of LVAD Cannula

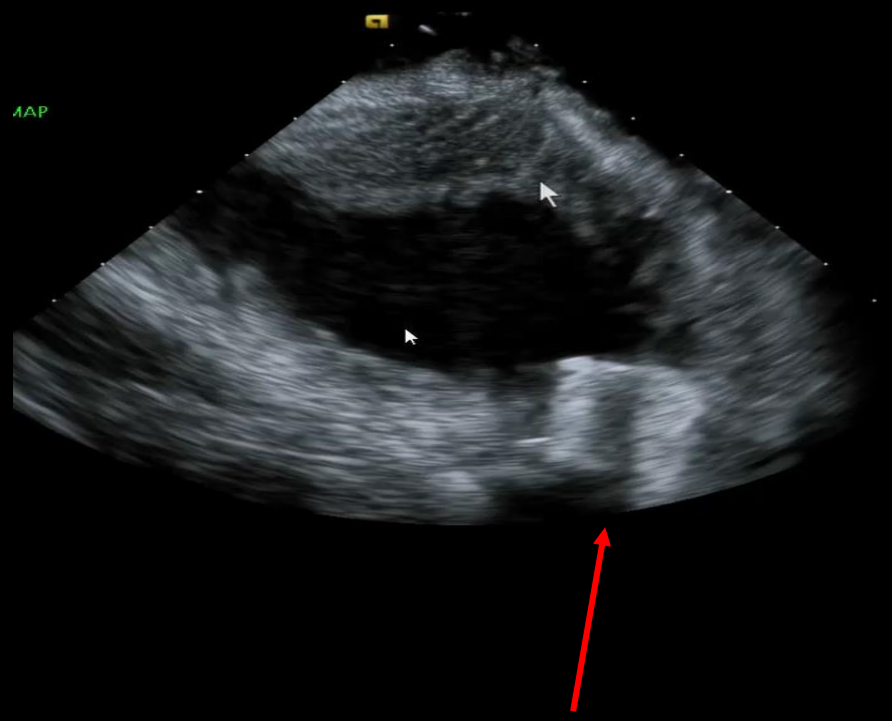

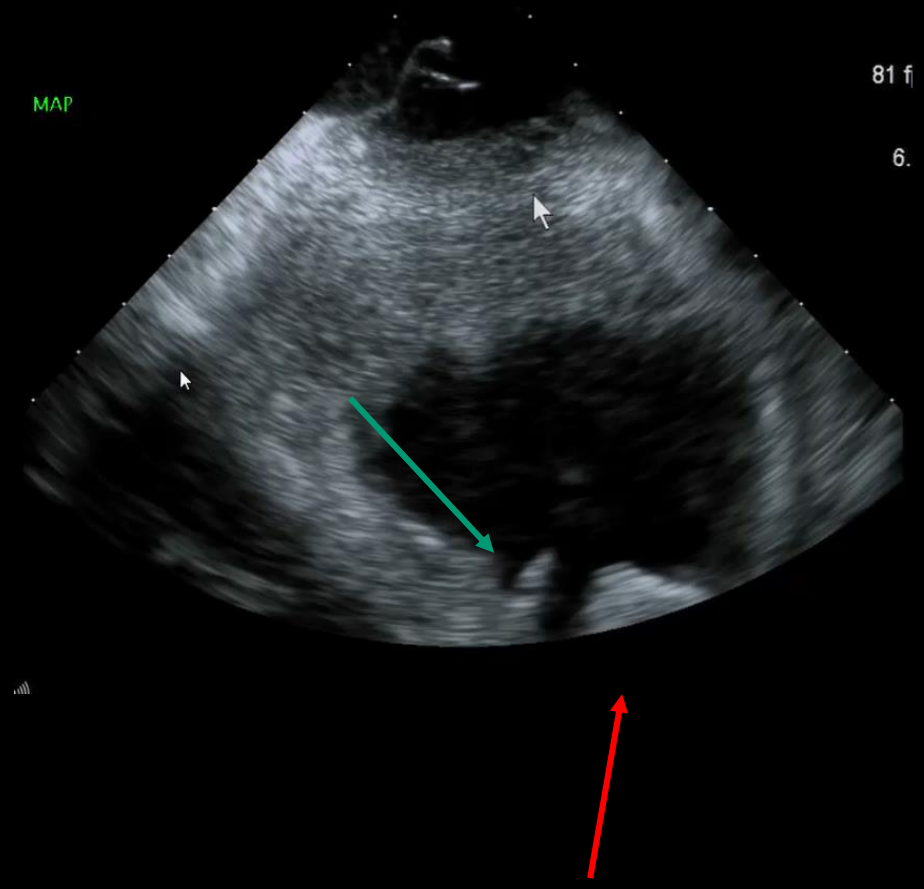

Needle ablation for VT

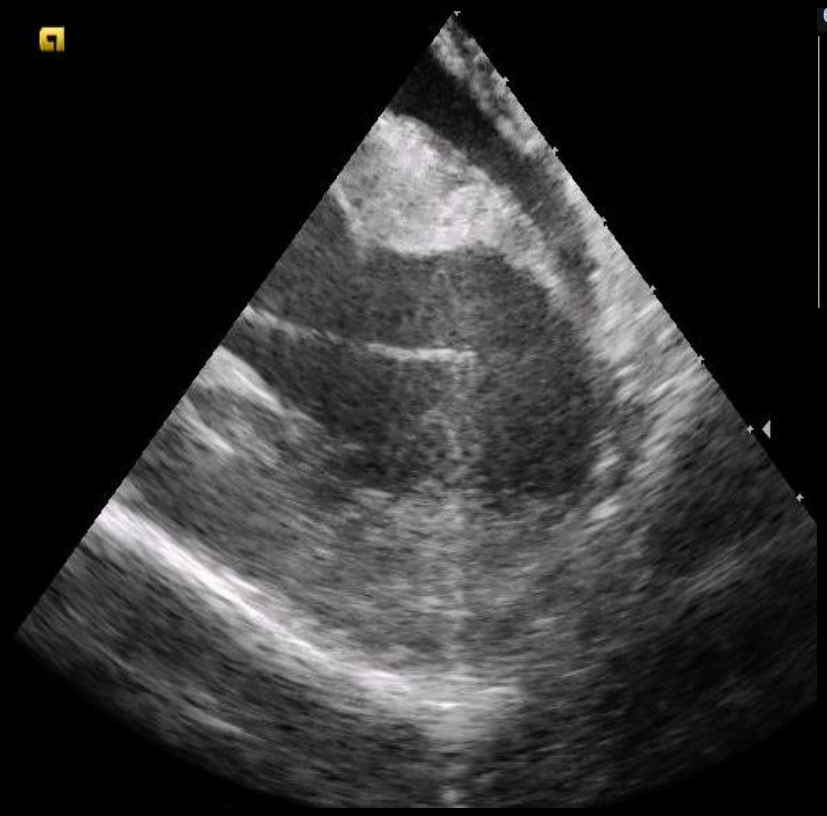

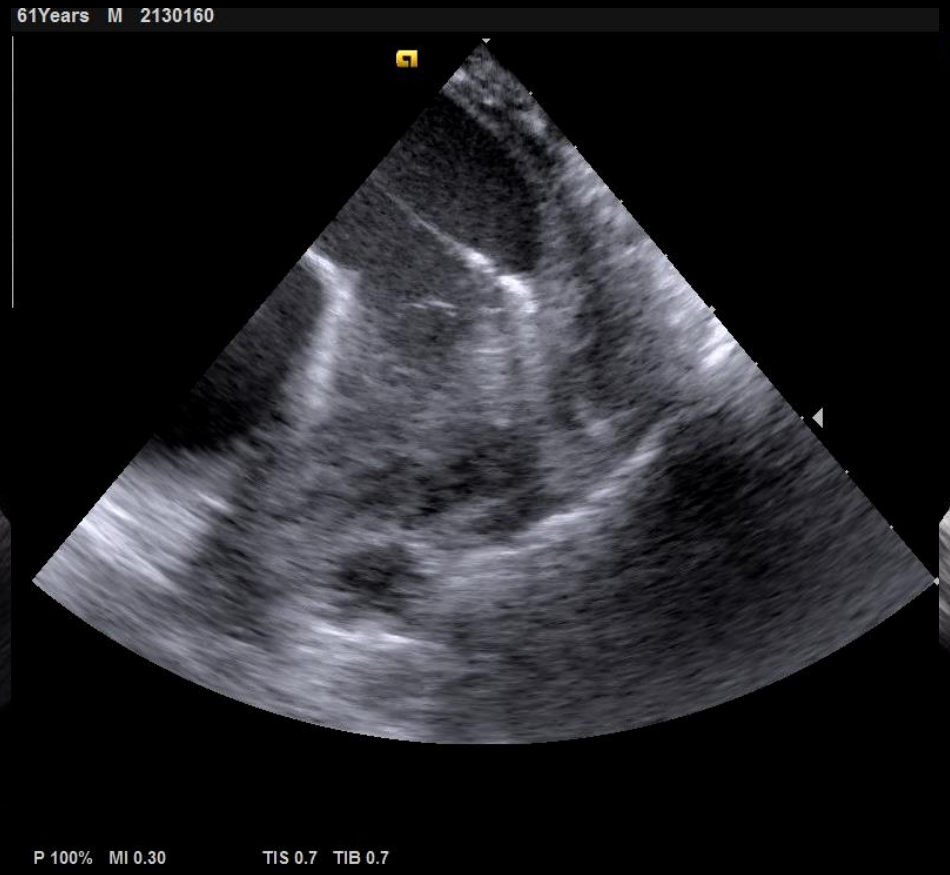

Lesion directed at the apical septum

Lesion in the inferior lateral wall

Utility of ICE for VA
(above and beyond that of mapping systems and Xray)

- For idiopathic VT
  - Creation of Right ventricular and LV outflow tract anatomy
  - Location of Critical strictures- R and L coronary cusp, Left main artery
  - Identification of site of ablation catheter- below the aortic cusp or above, identification of pulmonary annulus to identify PA cusp VA
  - Identifying endocavitary structures- papillary muscles, moderator band -site of origin

Outflow Tract VT workflow
Anatomical reconstruction of RV

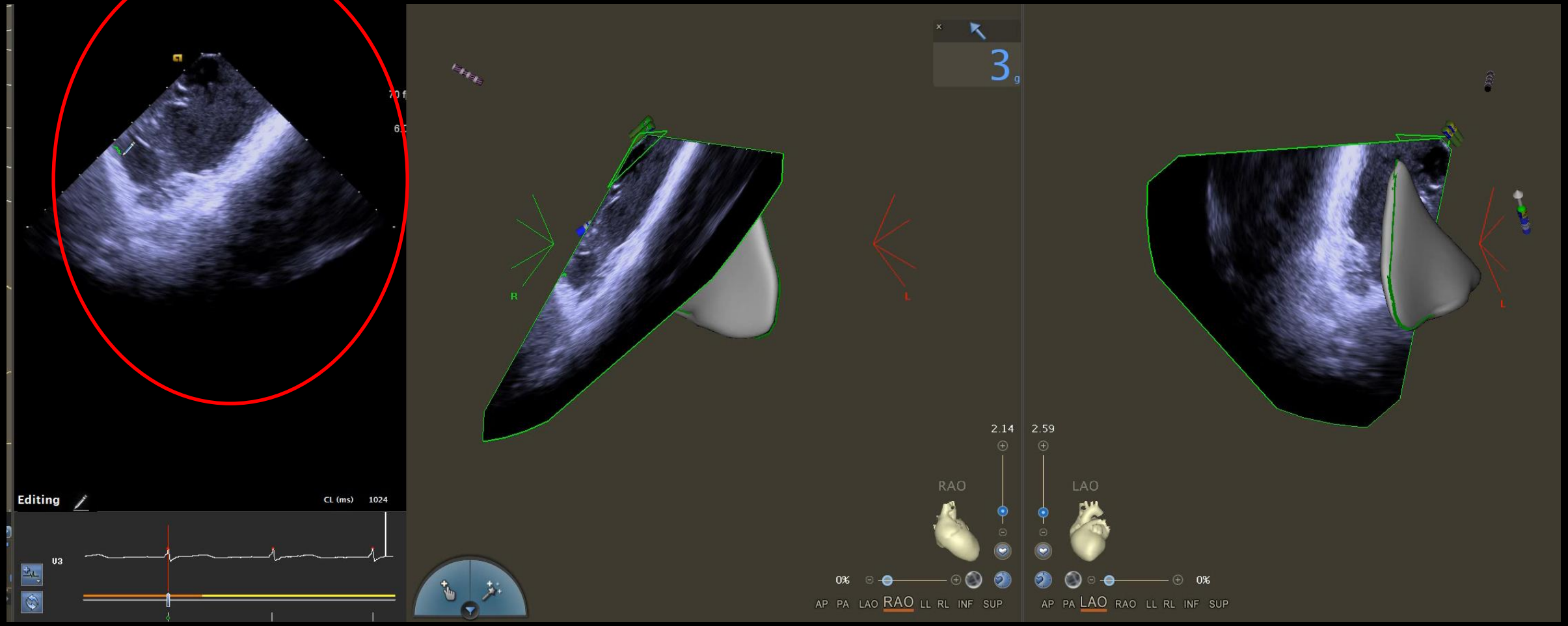

Anatomical Reconstruction RV

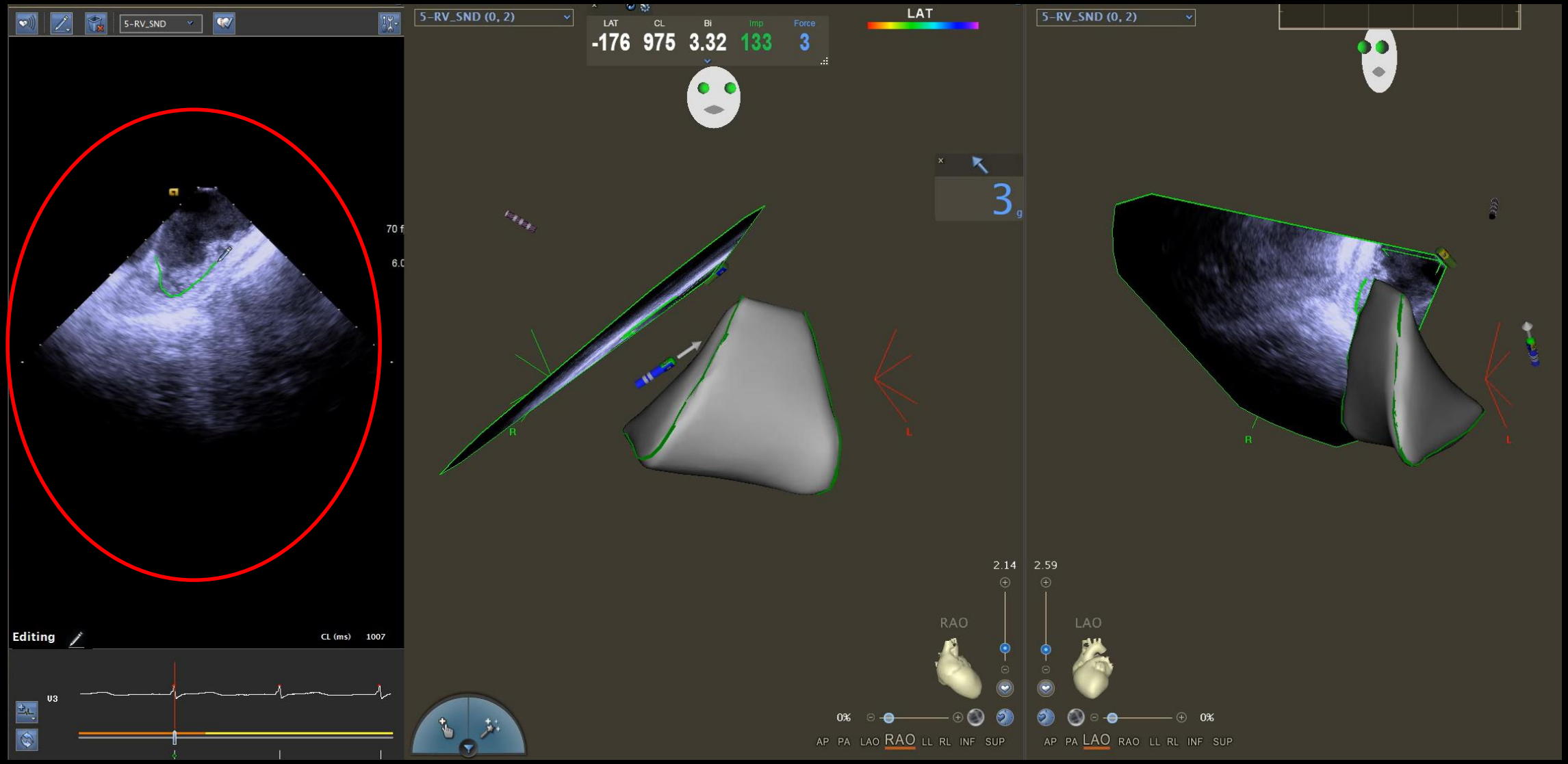

Anatomical Reconstruction of RVOT

Anatomical reconstruction of the LVOT

Specific advantages of ICE imaging

- LVOT
  - Reduce the need for coronary angiography prior to cusp ablation for LVOT VT
  - If in long axis view the catheter is in cusp nadir- then safe to ablate or if near junction of cusps

- Papillary VT & Moderator band VA
  - Complex anatomical rendering
  - Ensure contact is on the papillary muscle and not the adjacent walls

ICE for Tricuspid valve arrhythmias

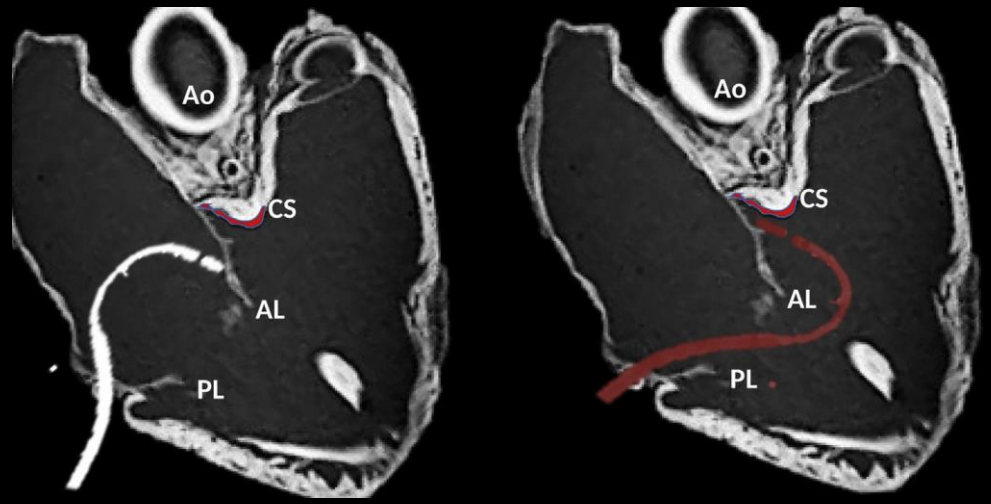

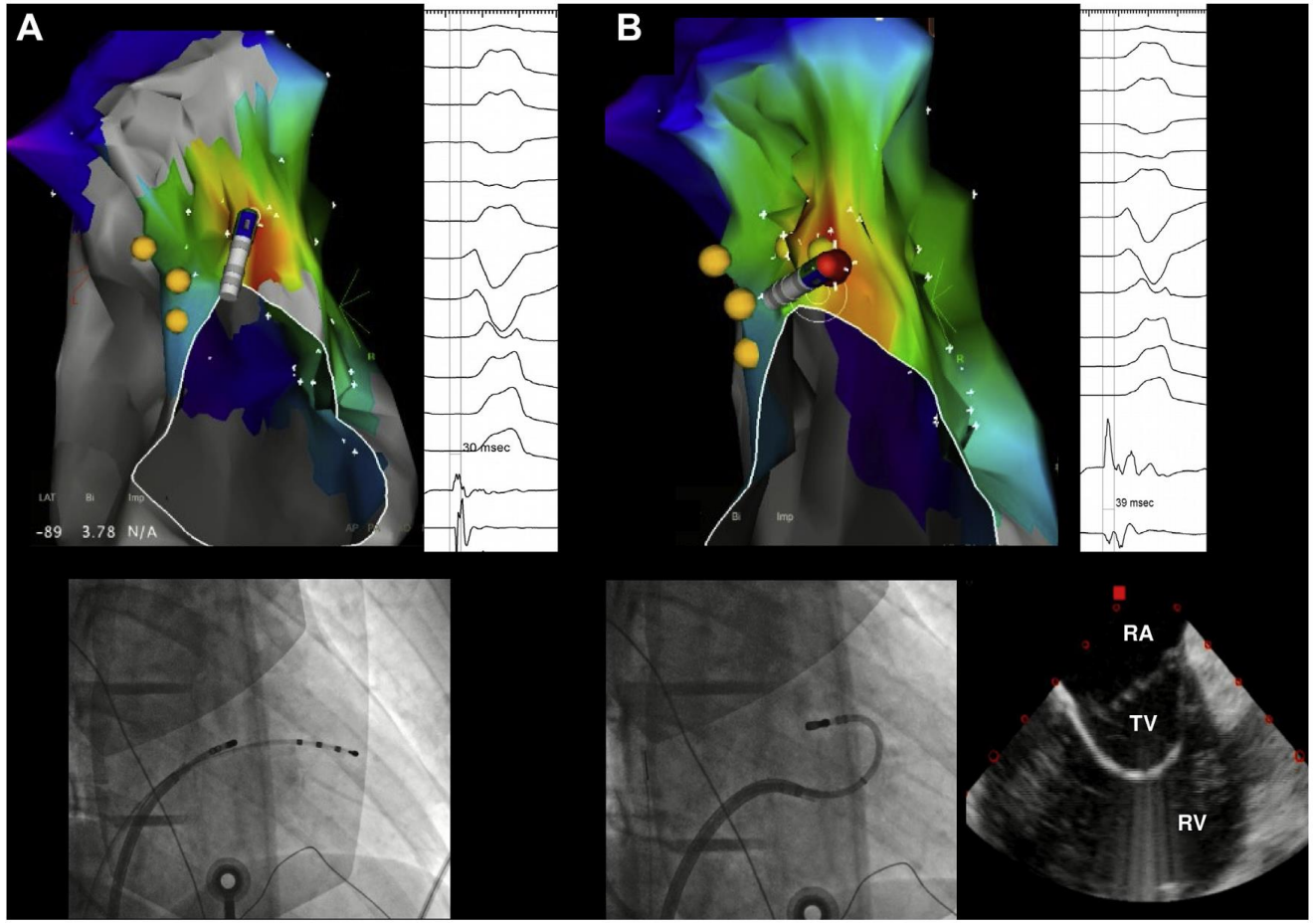

Enriquez, Garcia: HR case reports 2018

Anterolateral Papillary muscle

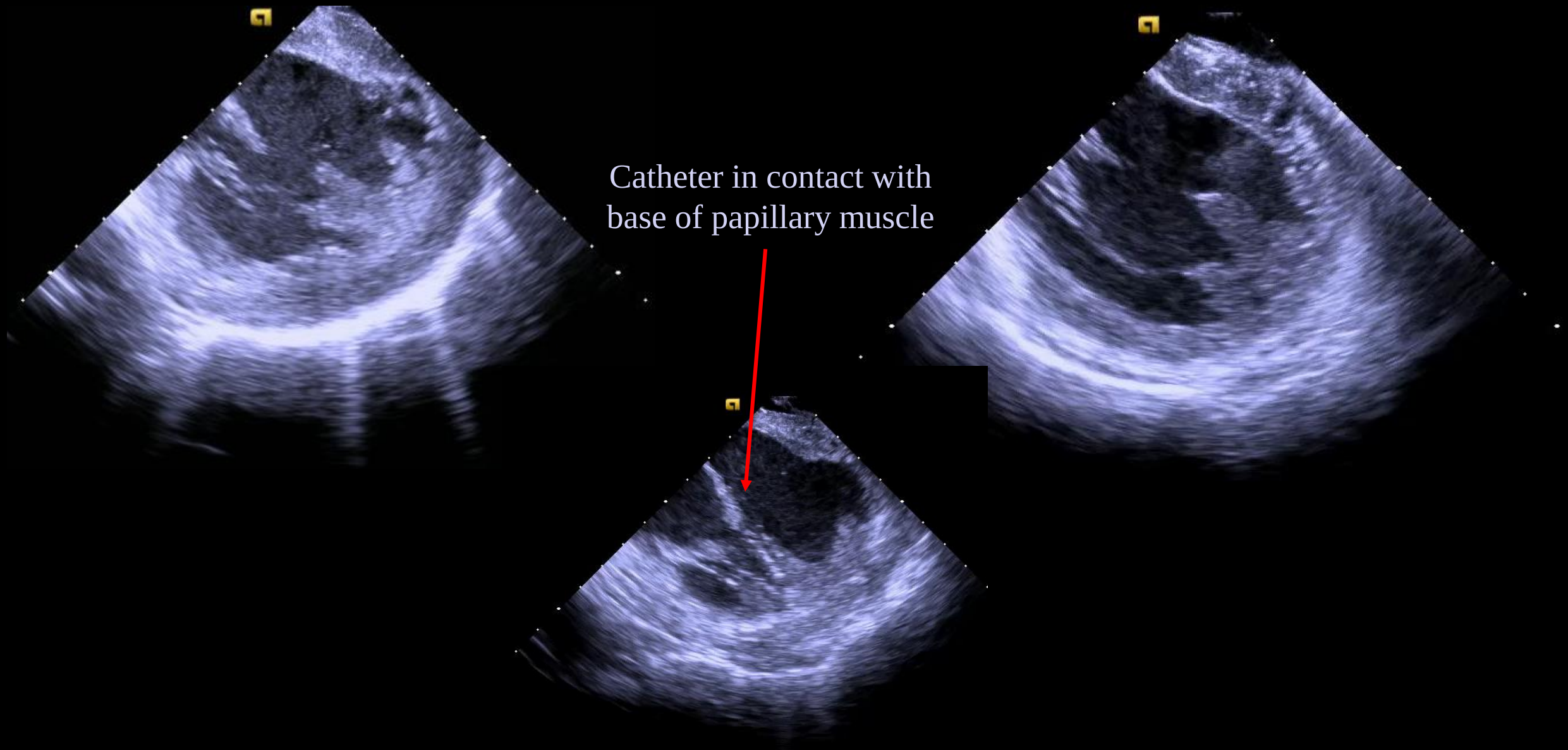

Posteromedial Papillary Muscle

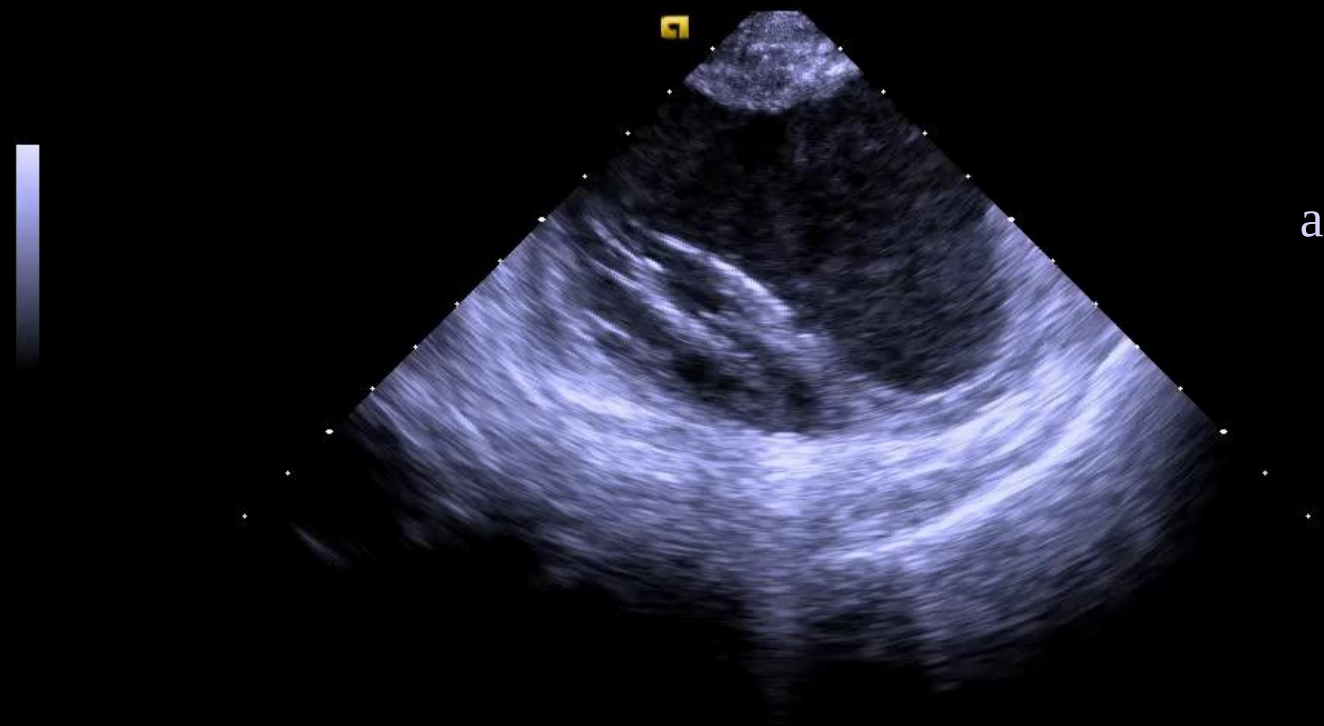

Catheter in contact with apical and lateral aspect of papillary muscle

Complication Detection

- LV function monitoring (PEA, decompensation)
- Lesion monitoring- steam formation (suggesting impending pop formation)
- Pericardial effusion/ thrombus

Steam formation and Steam Pop- Swine *In vivo*

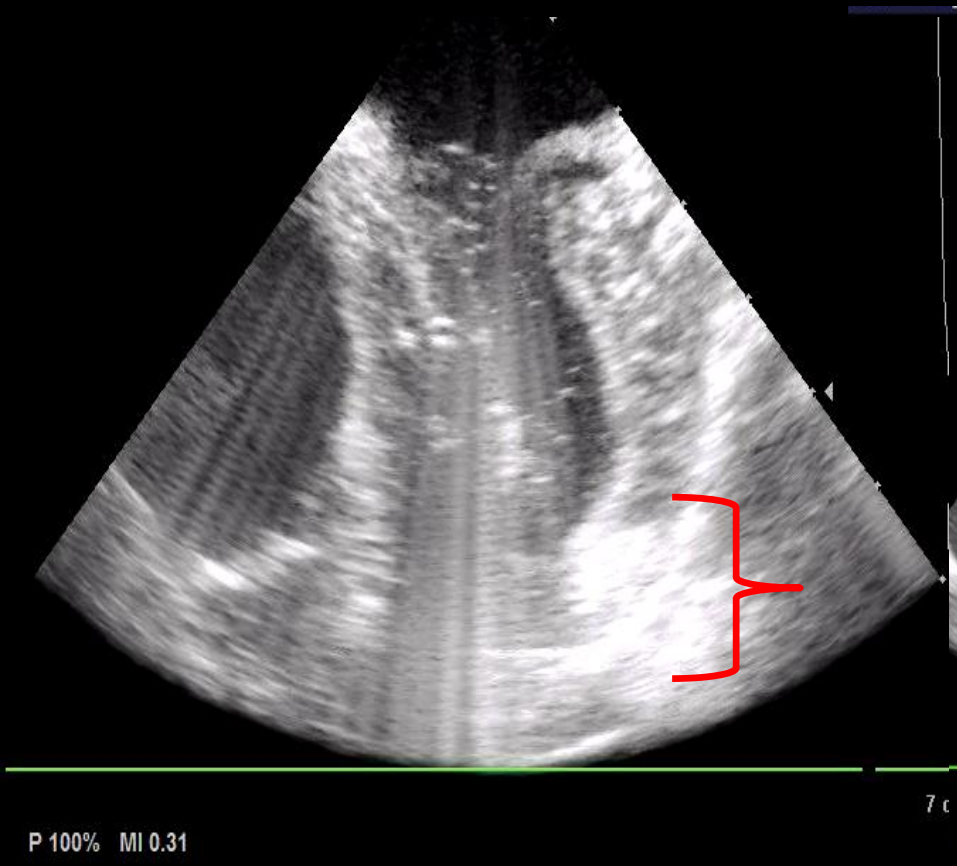

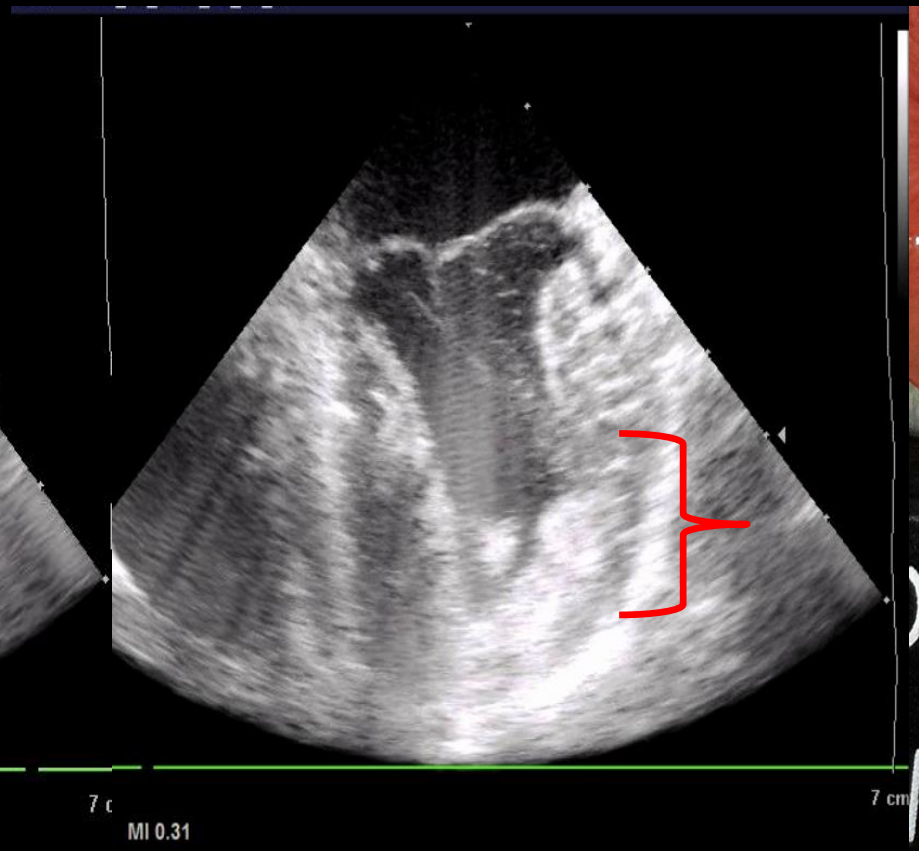

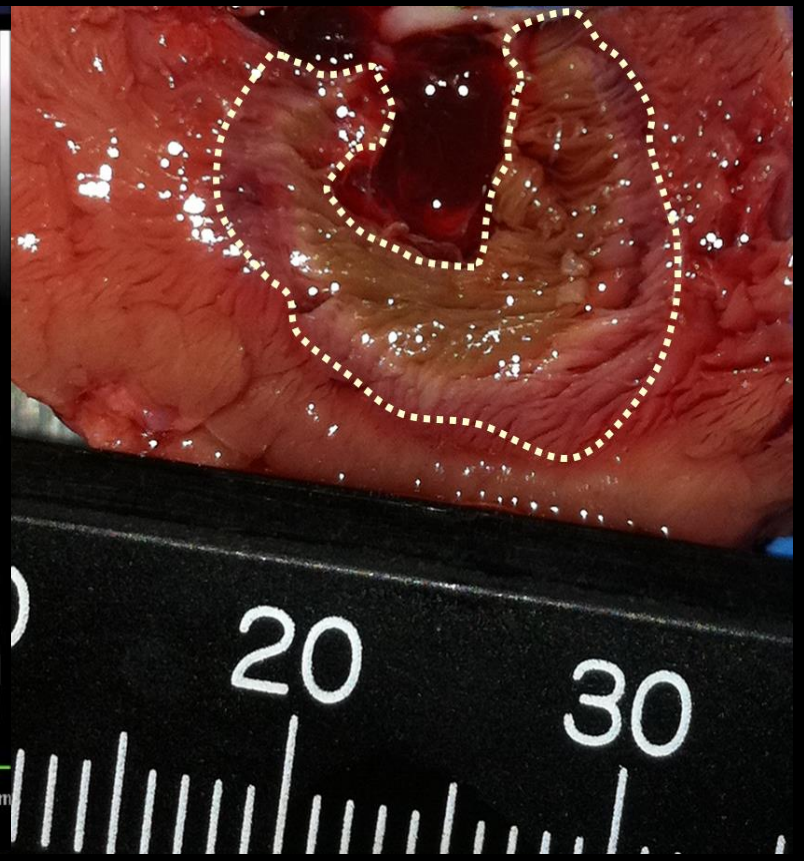

Complications

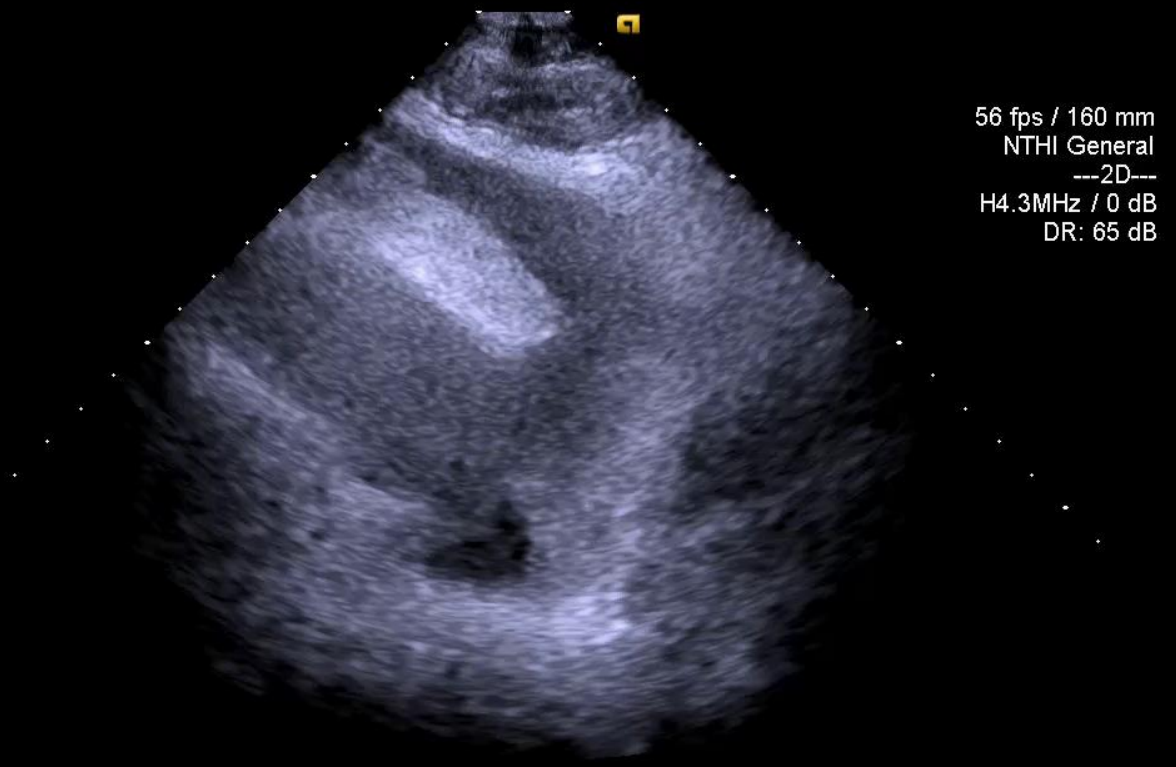

Loculated Effusion with Thrombus

Thank you

Mount Sinai Hospital

4 D ICE

- 10F shaft, capable of being deflected and torqued, and an inner shaft capable of being telescoped and rotated within the outer shaft.
- An imaging transducer assembly is housed within a 10F tip mounted to the distal end of the inner shaft.
- The imaging field emanates perpendicular to the axis of one side of the imaging tip. A proximal handle allows the user to deflect the outer shaft and to advance/rotate the inner shaft relative to the outer shaft..

needle

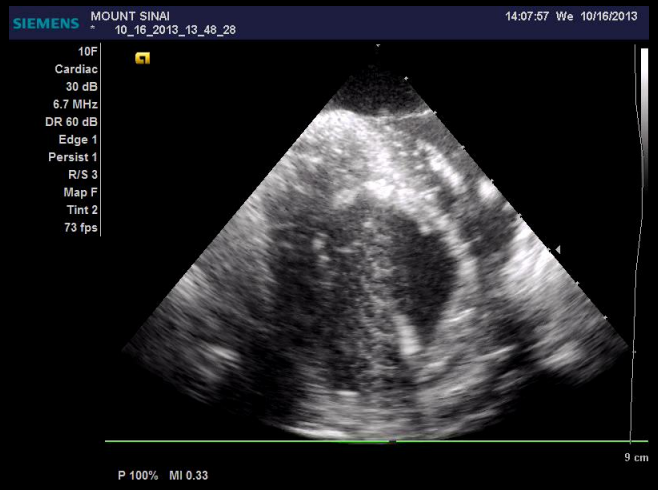
SIEMENS
MOUNT SINAI
10_16_2013_13_48_28
14:07:57 We 10/16/2013
10F
Cardiac
30 dB
6.7 MHz
DR 60 dB
Edge 1
Persist 1
R/S 3
Map F
Tint 2
73 fps
9 cm
P 100% MI 0.33

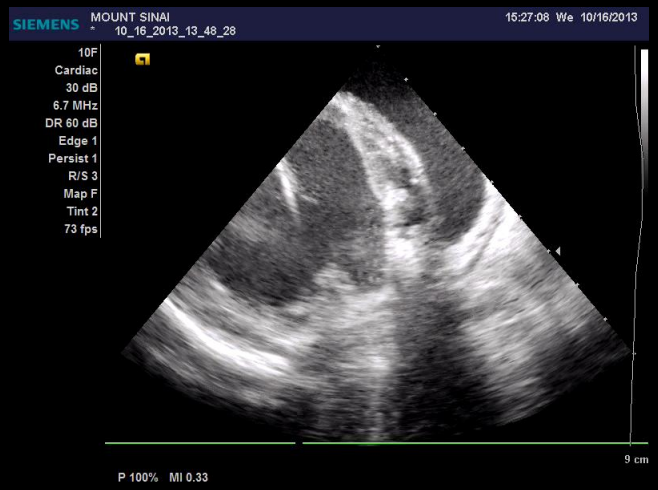
SIEMENS
MOUNT SINAI
10_16_2013_13_48_28
15:27:08 We 10/16/2013
10F
Cardiac
30 dB
6.7 MHz
DR 60 dB
Edge 1
Persist 1
R/S 3
Map F
Tint 2
73 fps
9 cm
P 100% MI 0.33

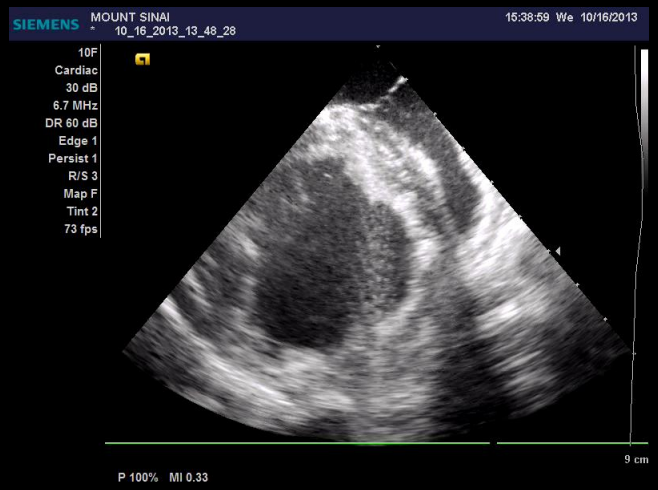
SIEMENS
MOUNT SINAI
10_16_2013_13_48_28
15:38:59 We 10/16/2013
10F
Cardiac
30 dB
6.7 MHz
DR 60 dB
Edge 1
Persist 1
R/S 3
Map F
Tint 2
73 fps
9 cm
P 100% MI 0.33

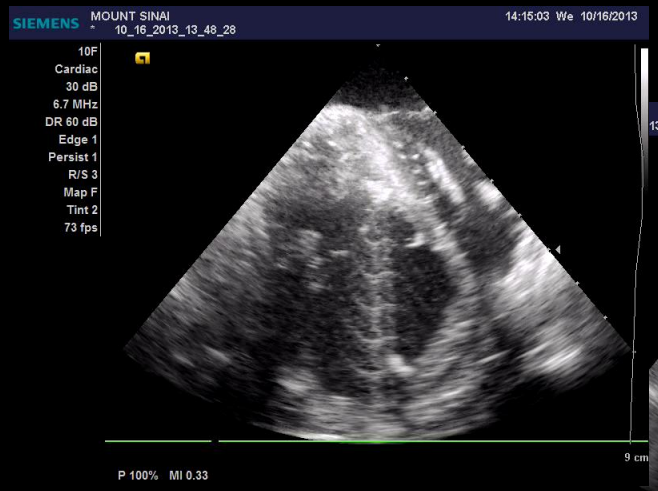
SIEMENS
MOUNT SINAI
10_16_2013_13_48_28
14:15:03 We 10/16/2013
10F
Cardiac
30 dB
6.7 MHz
DR 60 dB
Edge 1
Persist 1
R/S 3
Map F
Tint 2
73 fps
9 cm
P 100% MI 0.33

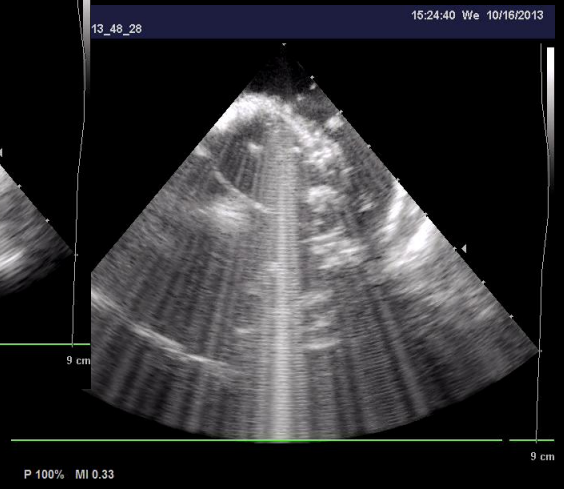
13_48_28
15:24:40 We 10/16/2013
9 cm
P 100% MI 0.33

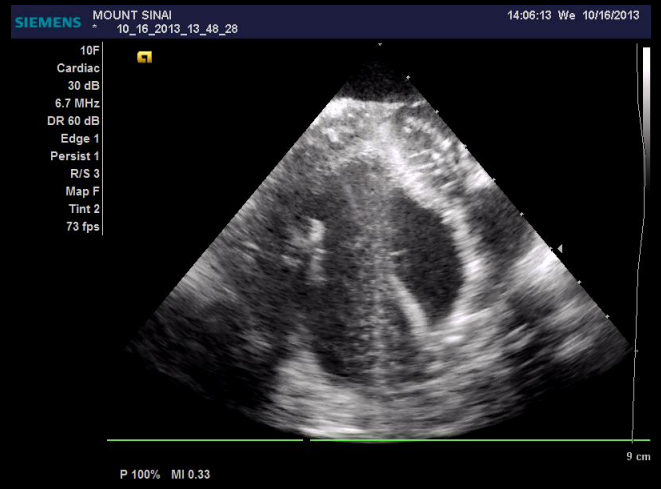
SIEMENS
MOUNT SINAI
10_16_2013_13_48_28
14:06:13 We 10/16/2013
10F
Cardiac
30 dB
6.7 MHz
DR 60 dB
Edge 1
Persist 1
R/S 3
Map F
Tint 2
73 fps
9 cm
P 100% MI 0.33